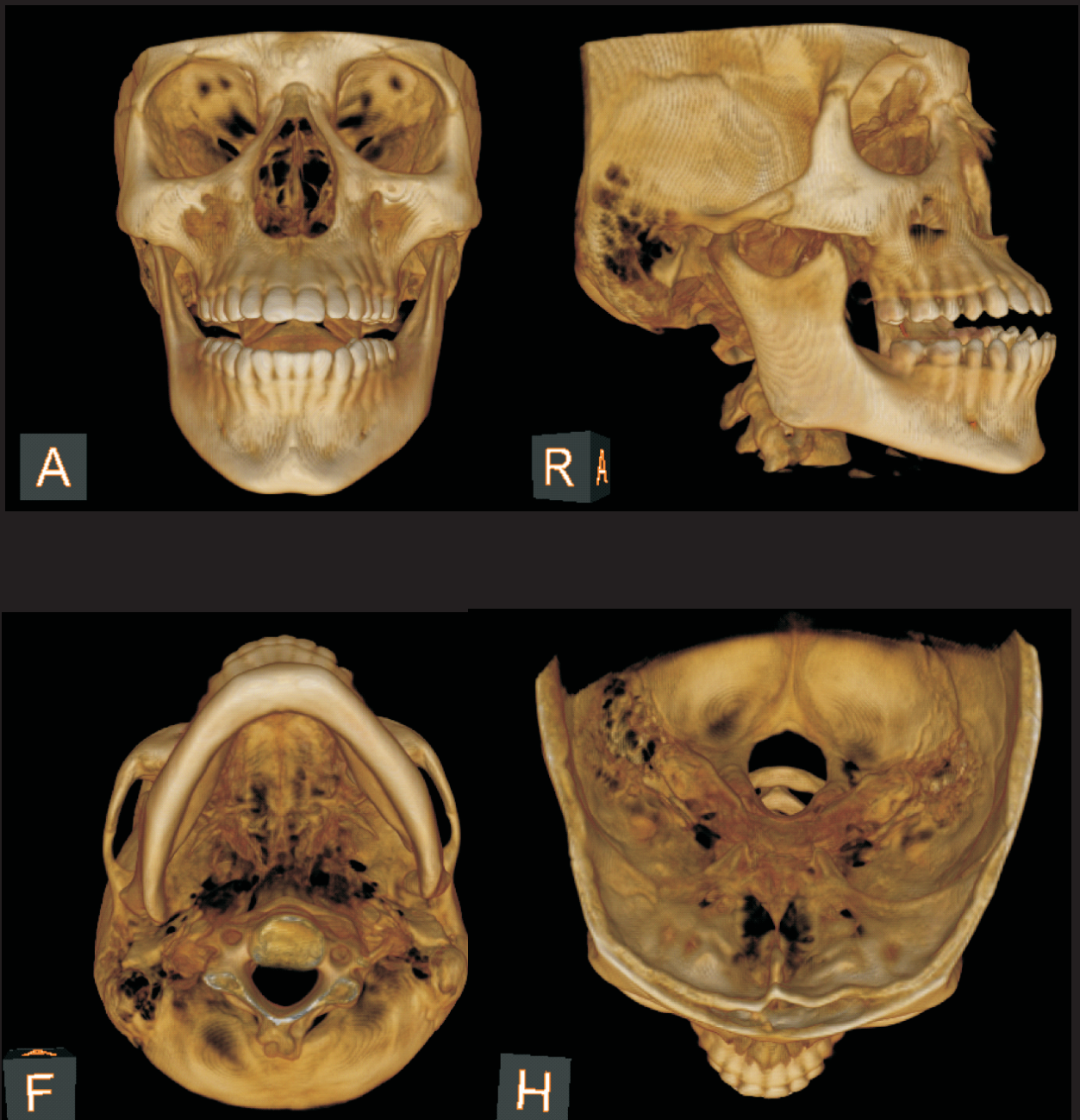
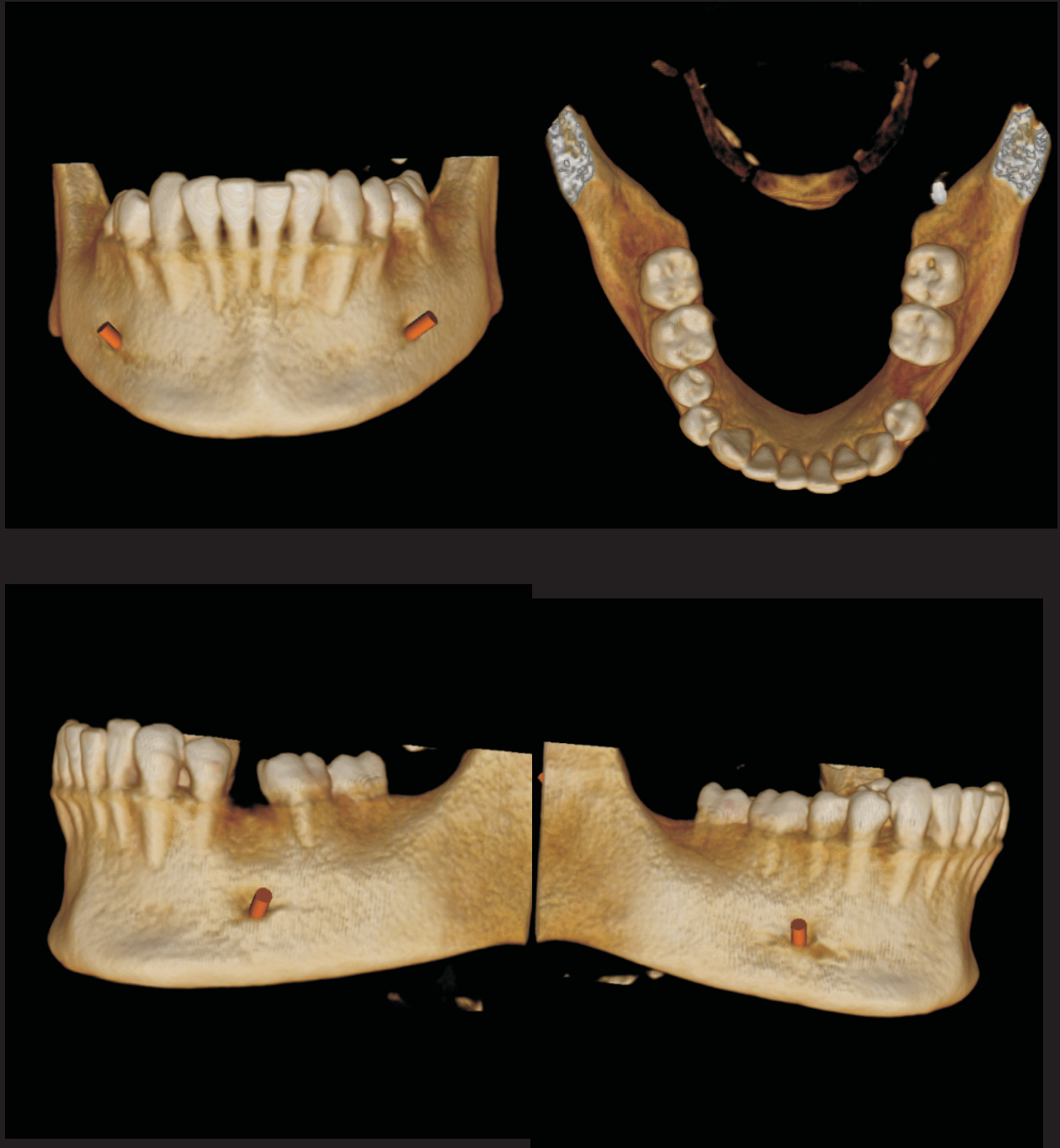
### 3 Dimensional View



Field of view (FOV) 17x13.55. Full skull

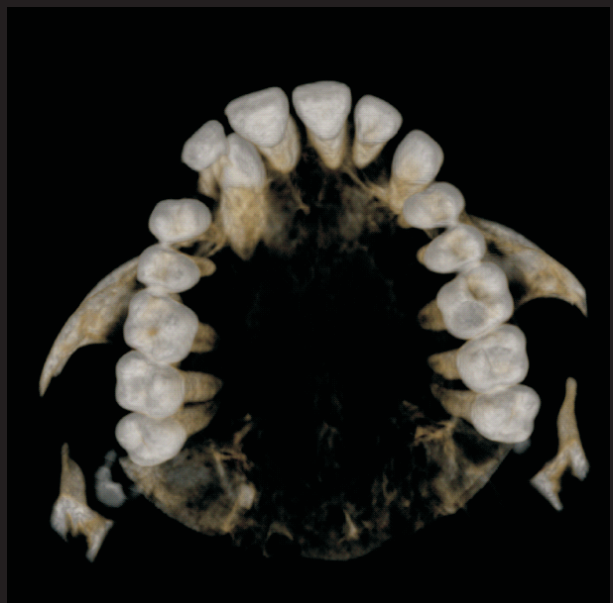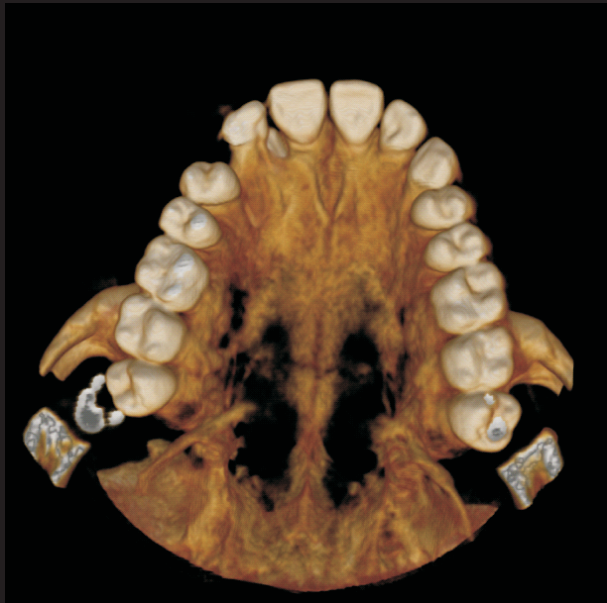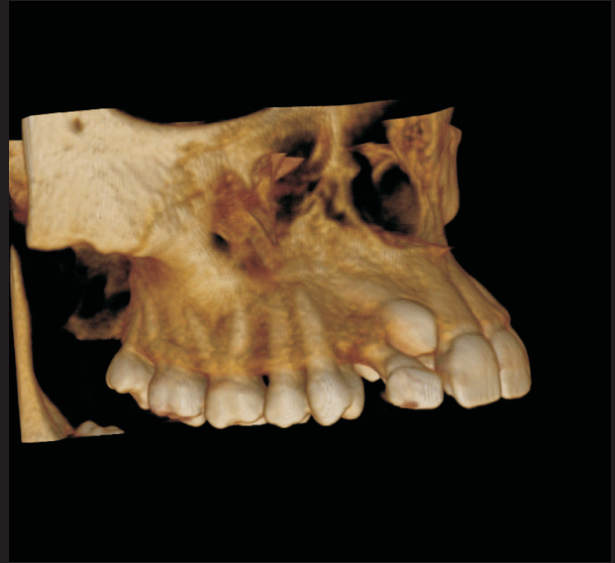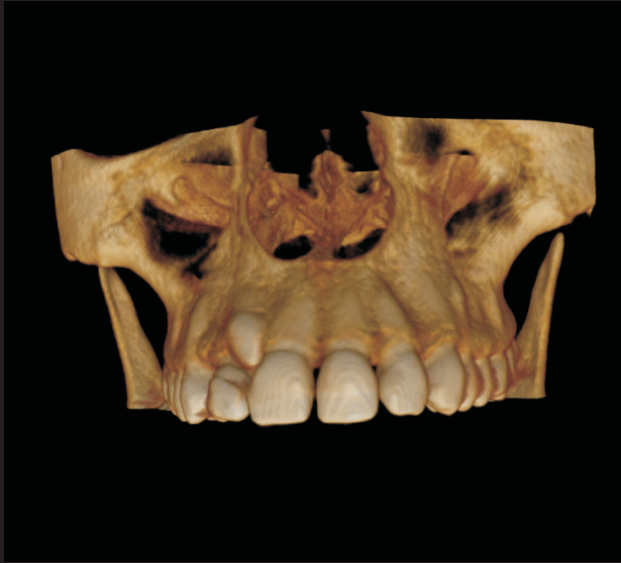### 3 Dimensional View



Field of view (FOV) 10x5. Mandible

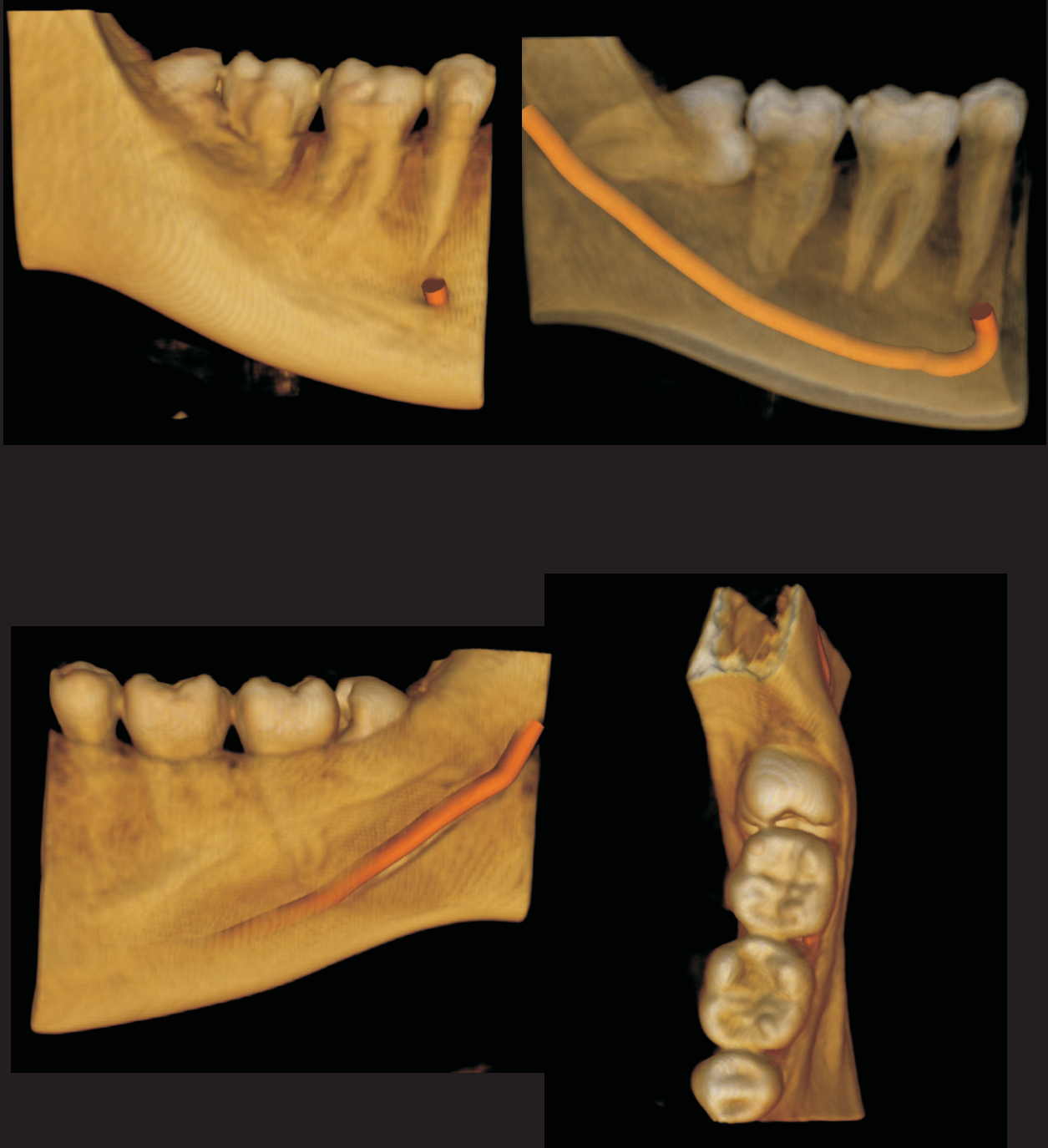

### 3 Dimensional view



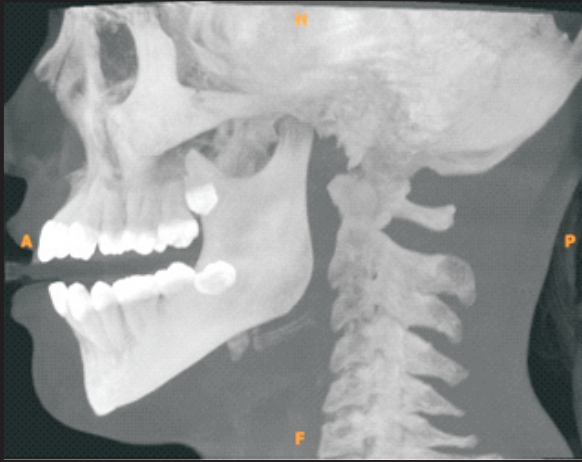
Field of view (FOV) 10x5. Maxilla

### 3 Dimensional view

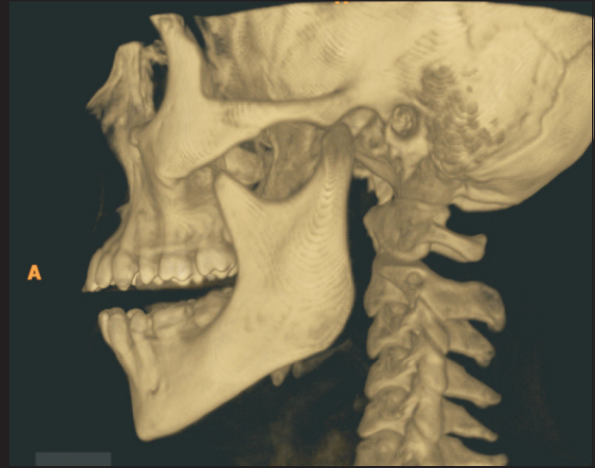

Field of view 5x5. Partial Mandible

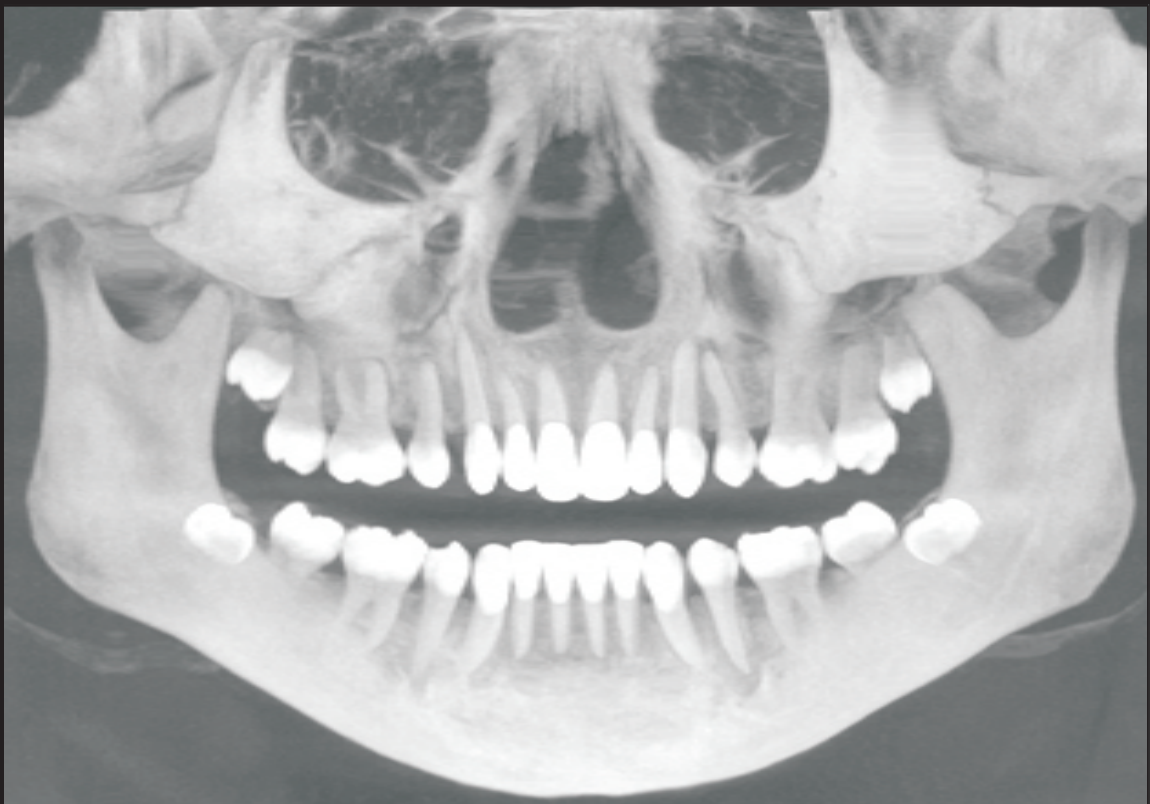## Maximum Intensity Projection



MIP Images Lateral View



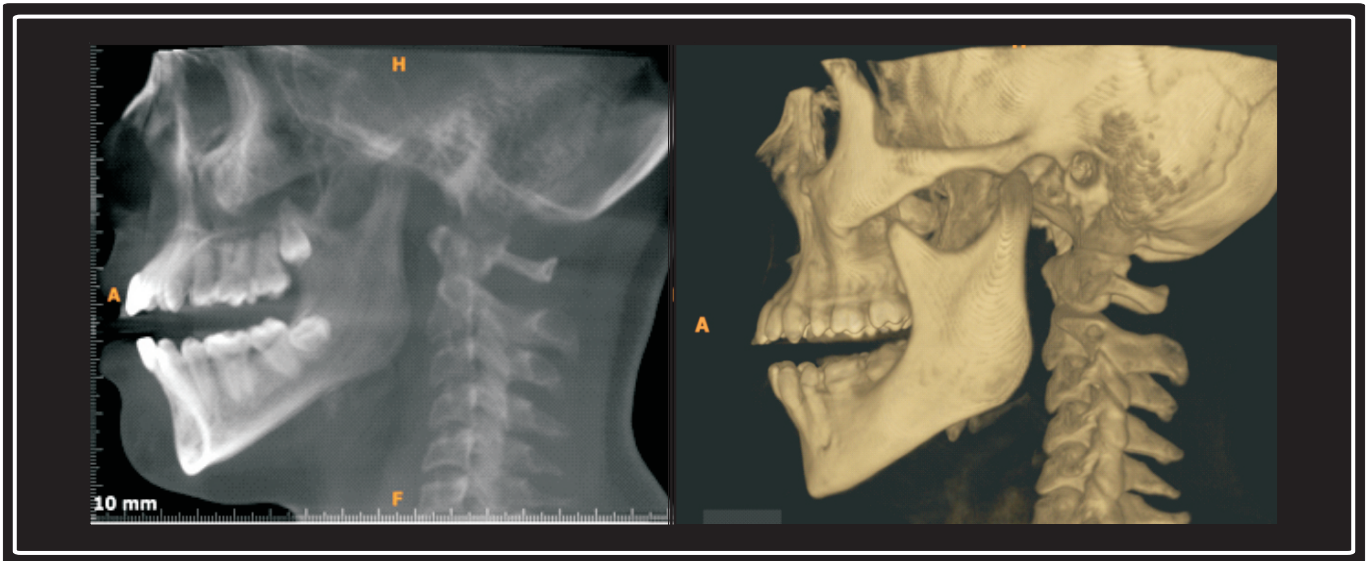
3D View Lateral Skull



MIP Images Panoramic view

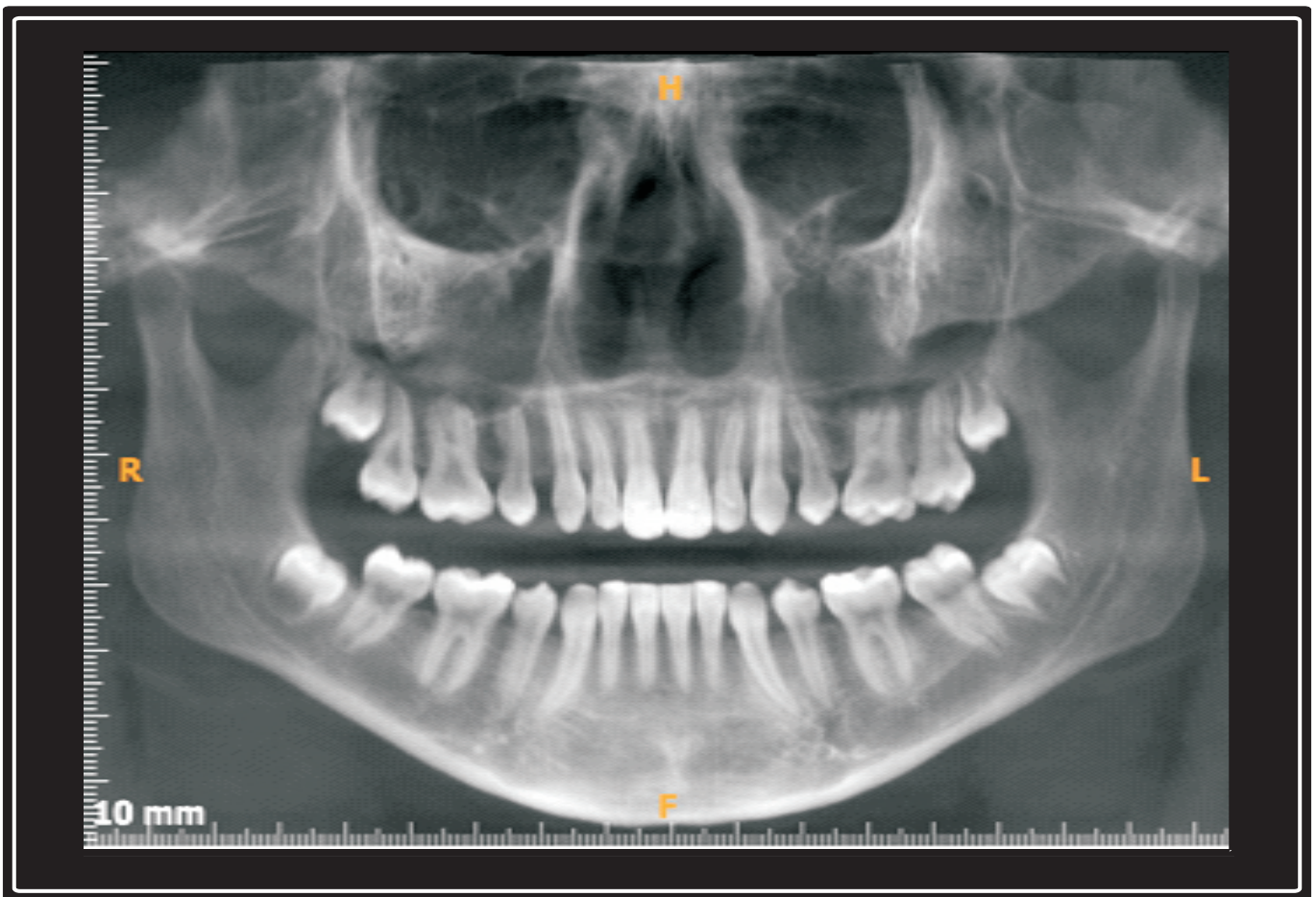

## Averaging Image



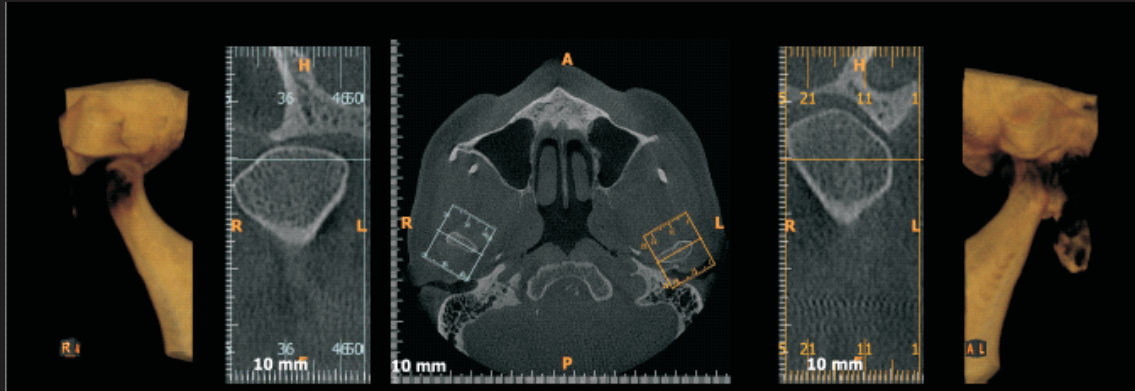
AVG image lateral view

3D view lateral skull



AVG Image Panoramic View

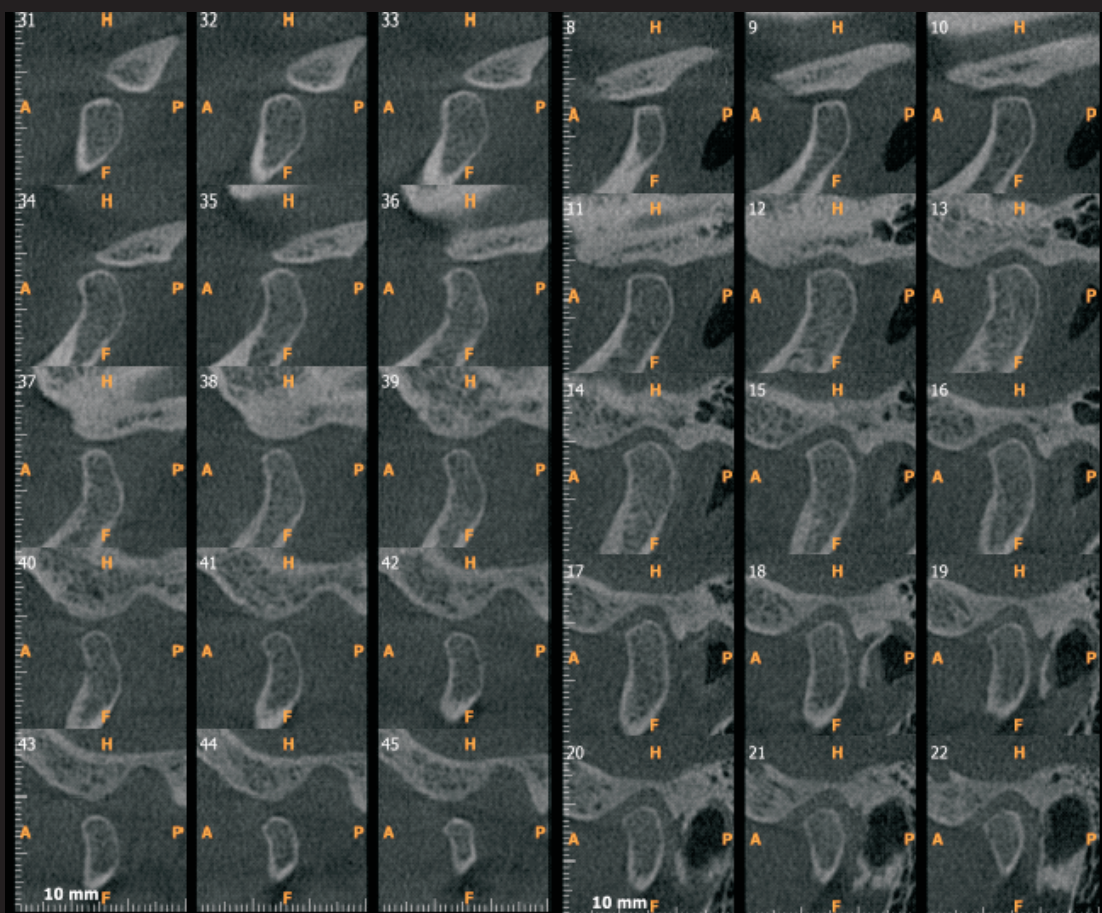
## Temperomandibular Joint



3D view  
right TMJ

Axial section

3D view  
left TMJ

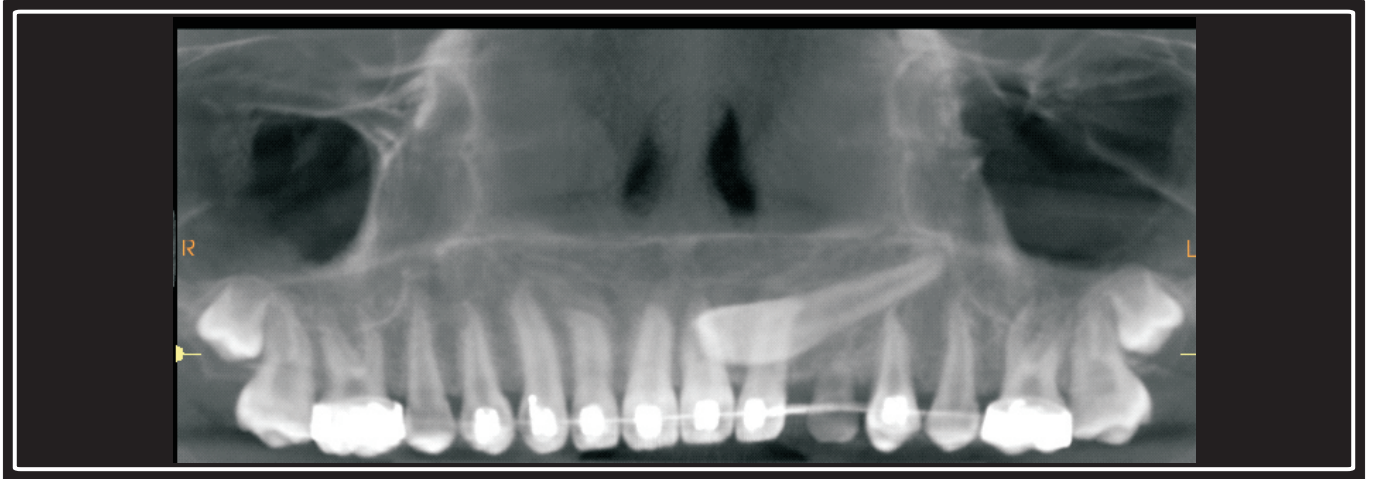


Right Side Sagittal Section

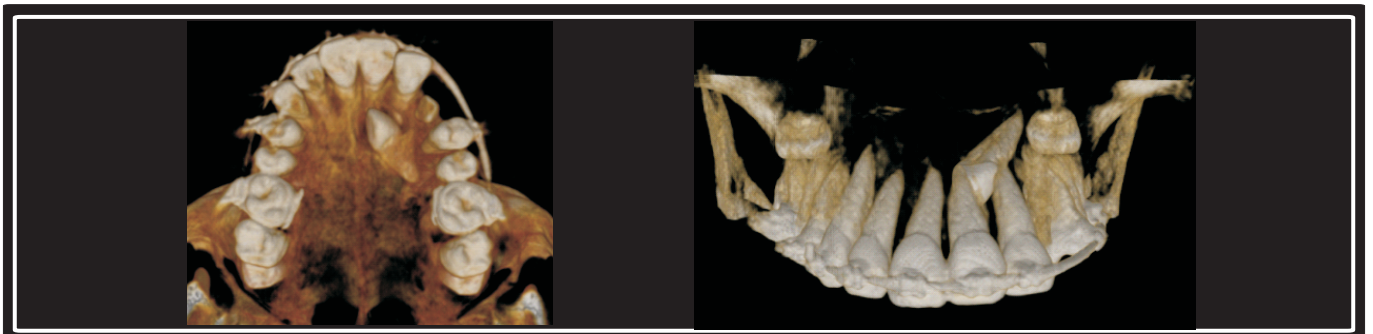
Left Side Sagittal Section



## Impacted Canine

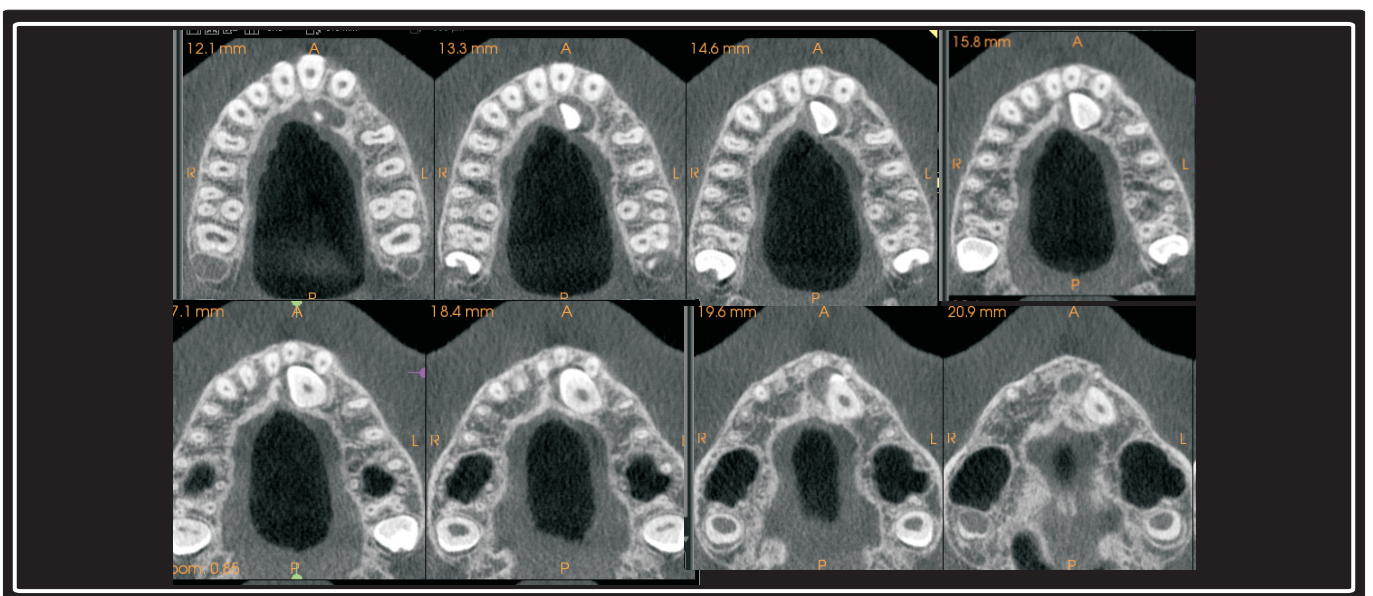


Reconstructed panoramic image



3D view

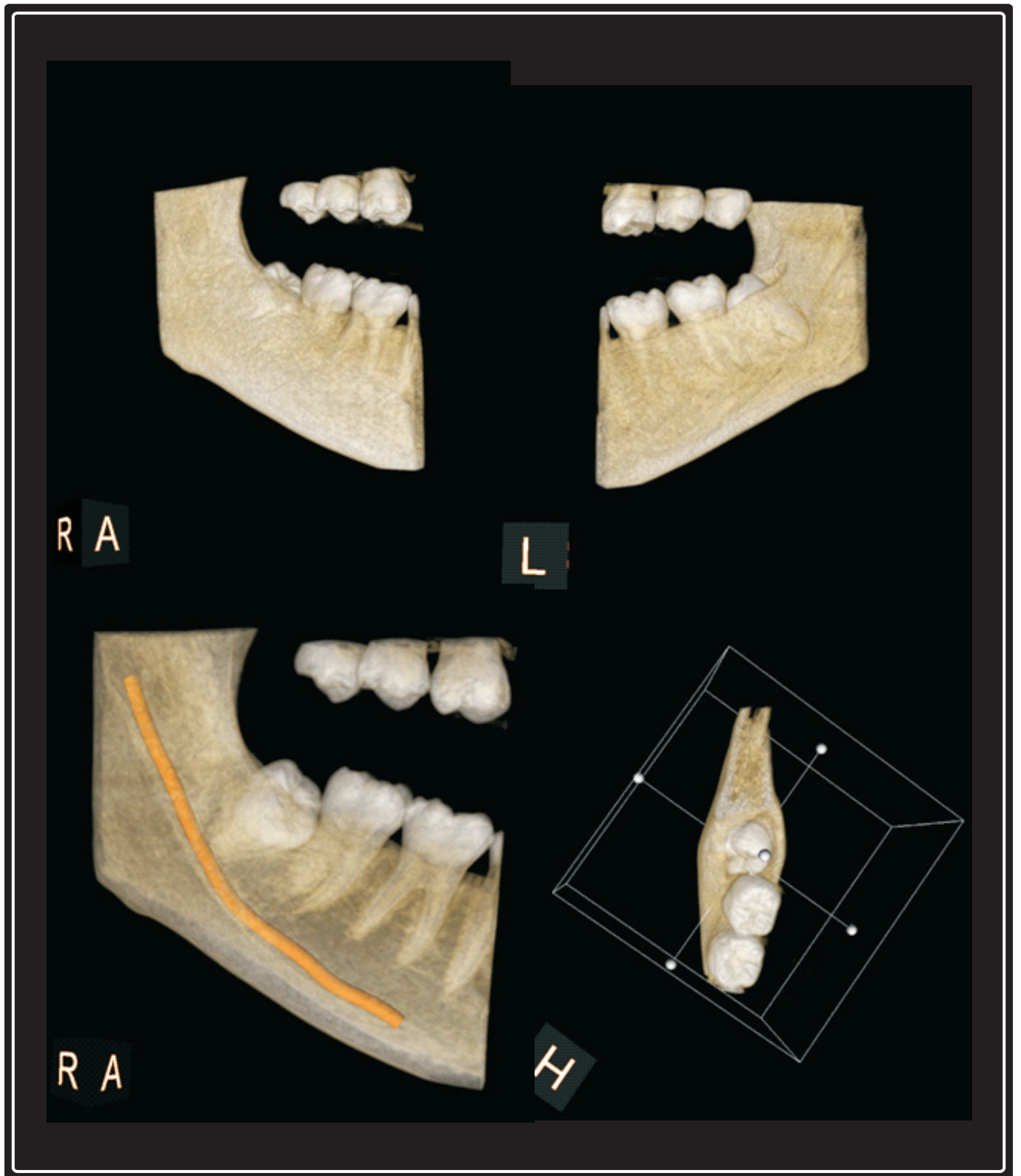
3D view transparent



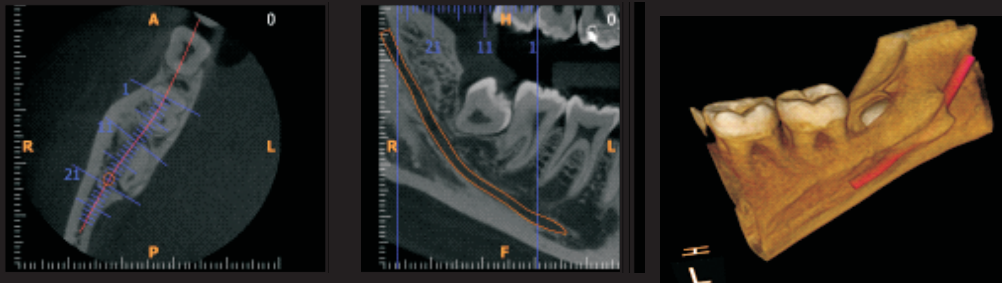
Axial View



## Impacted Mandibular Third Molar

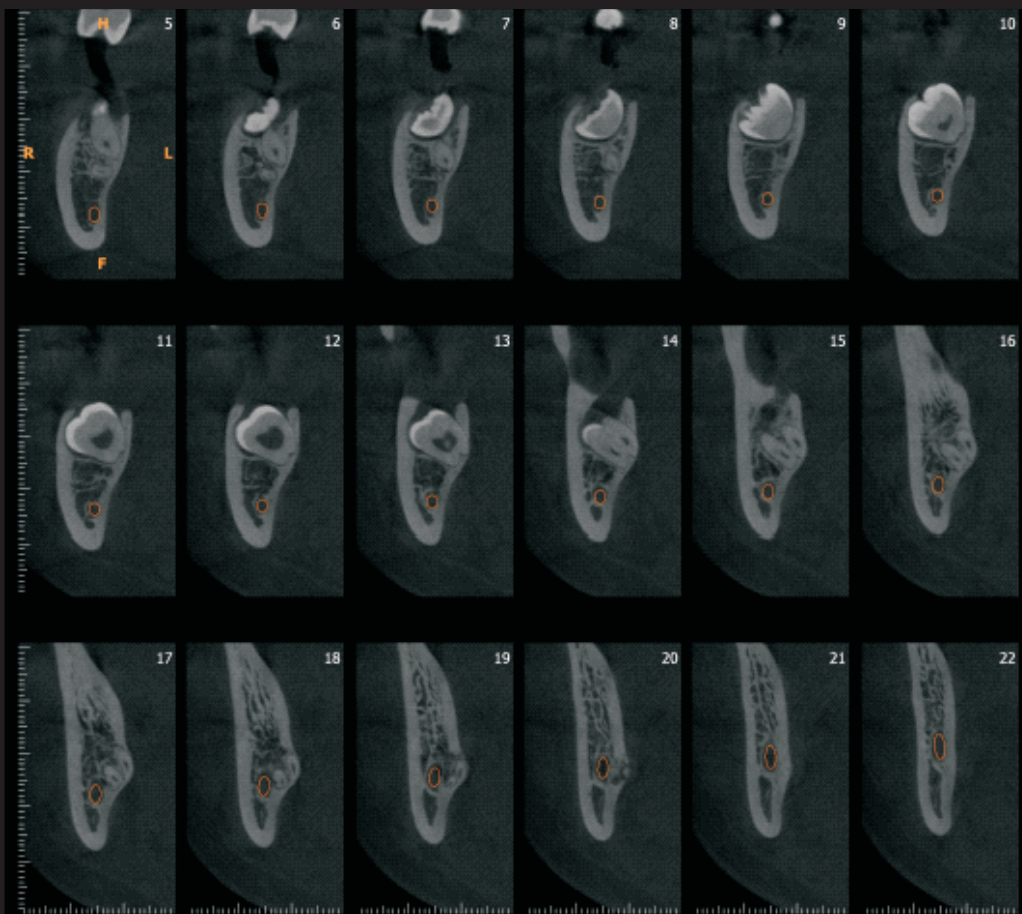


## Impacted Mandibular Third Molar



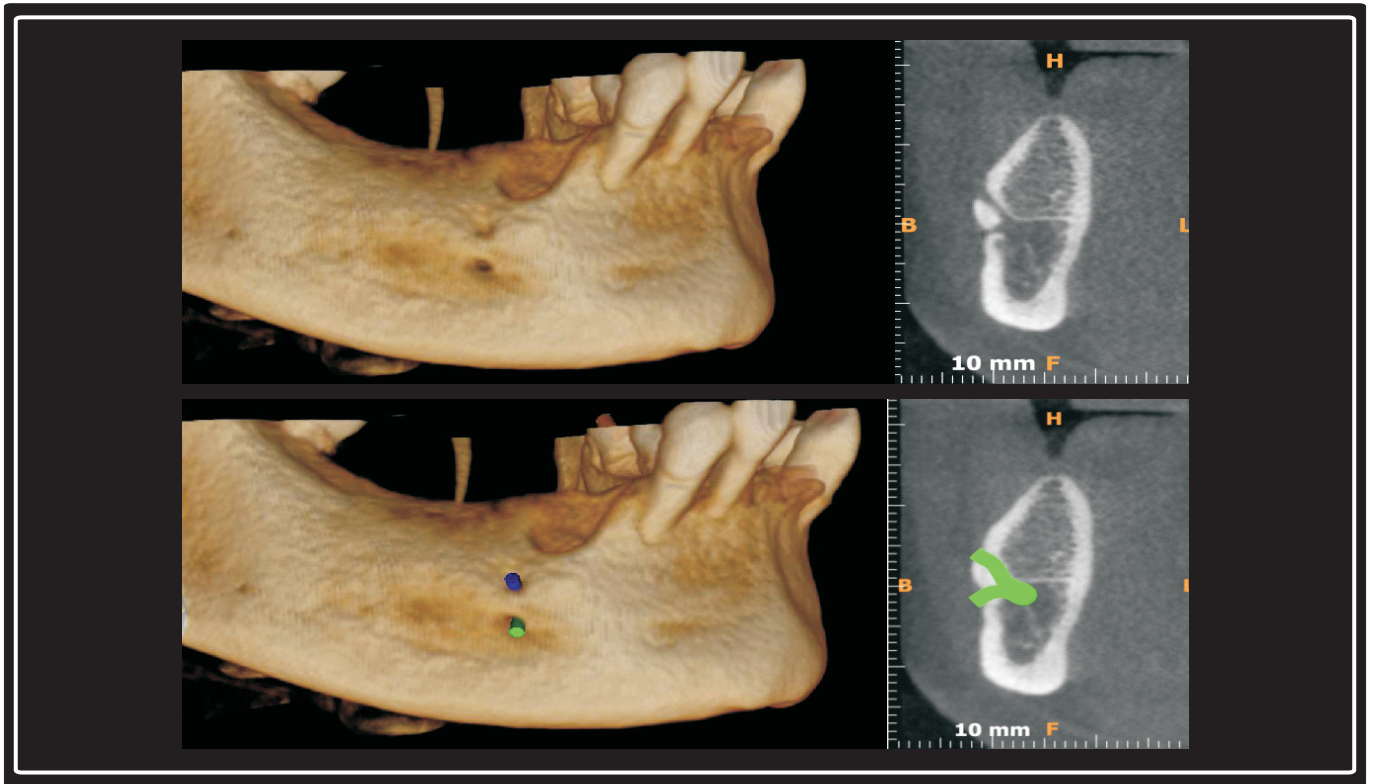
Axial Image

Reconstructed  
Panoramic Image

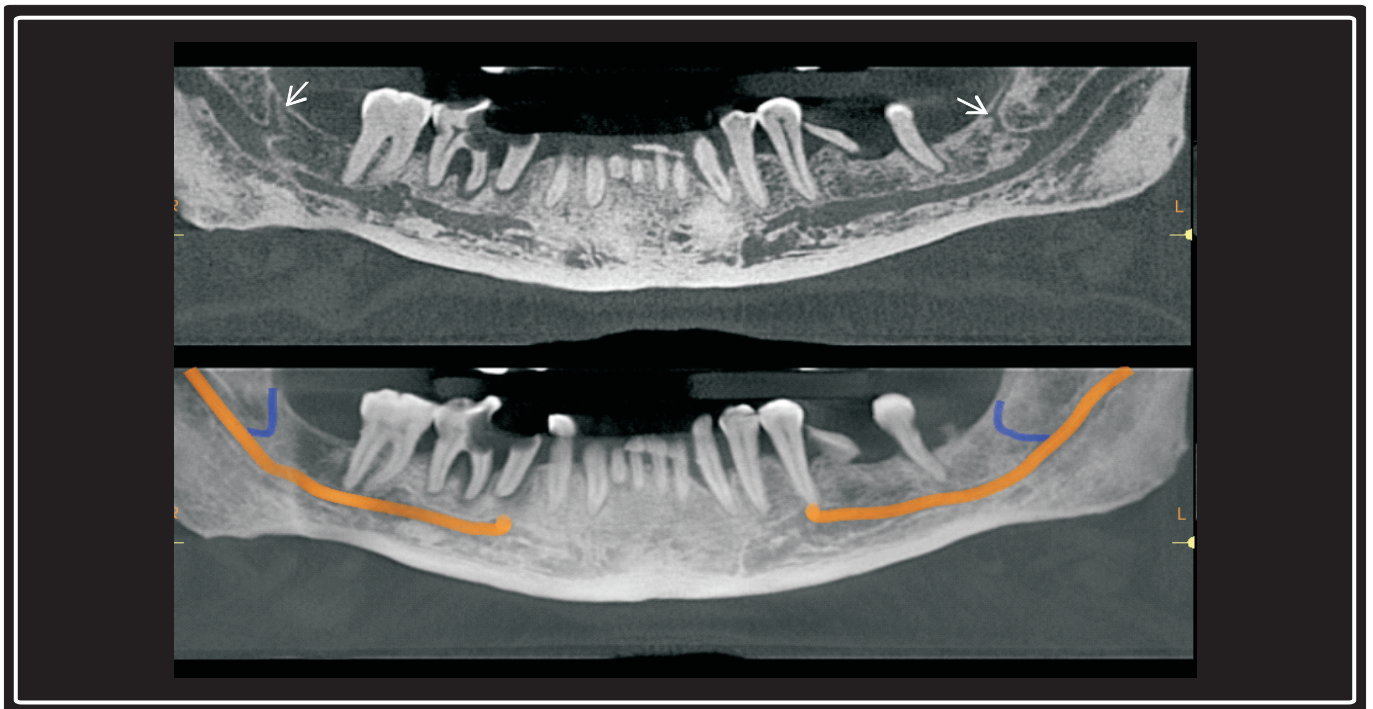


Crosssection Images - Slice thickness 0.18 mm, Slice spacing 1mm

## Anatomic Variation



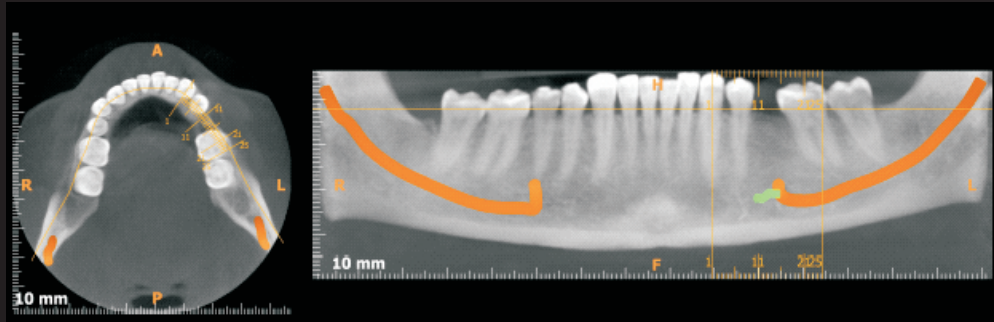
## Accessory Mental Foramen



## Retro Molar Canal

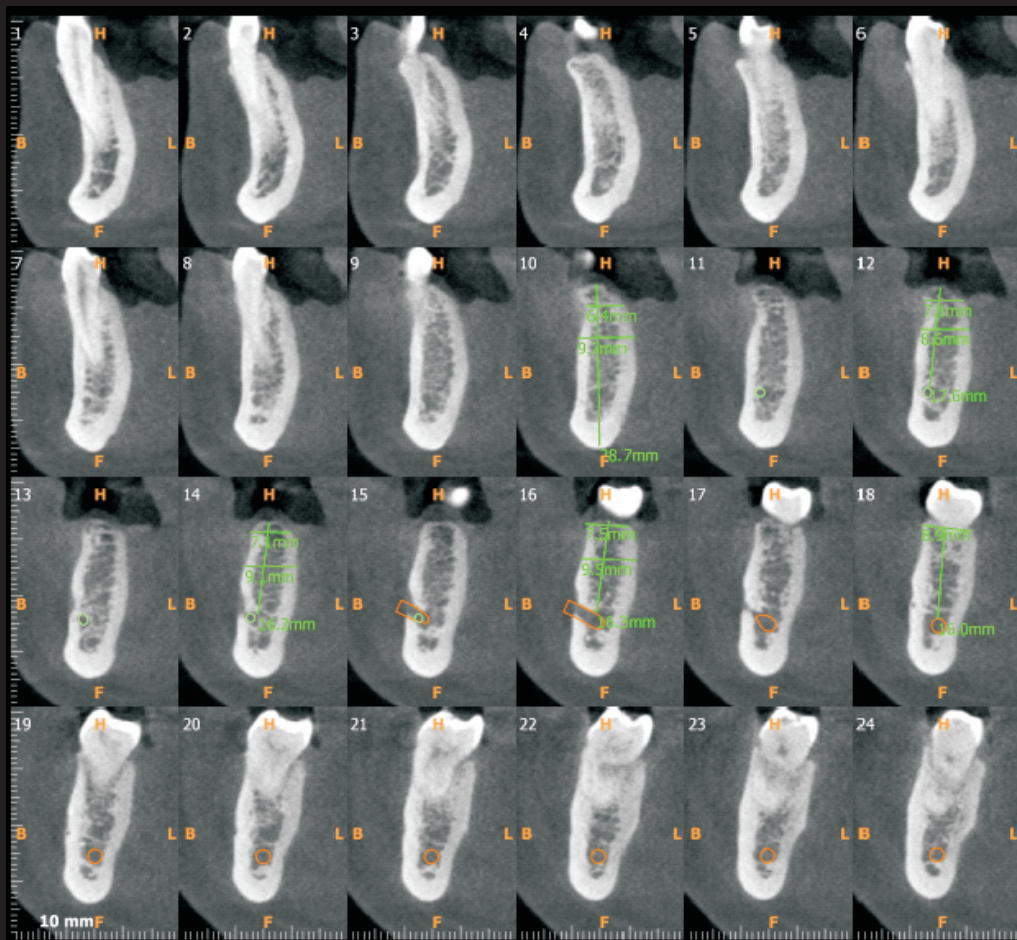


## Implant Site Evaluation



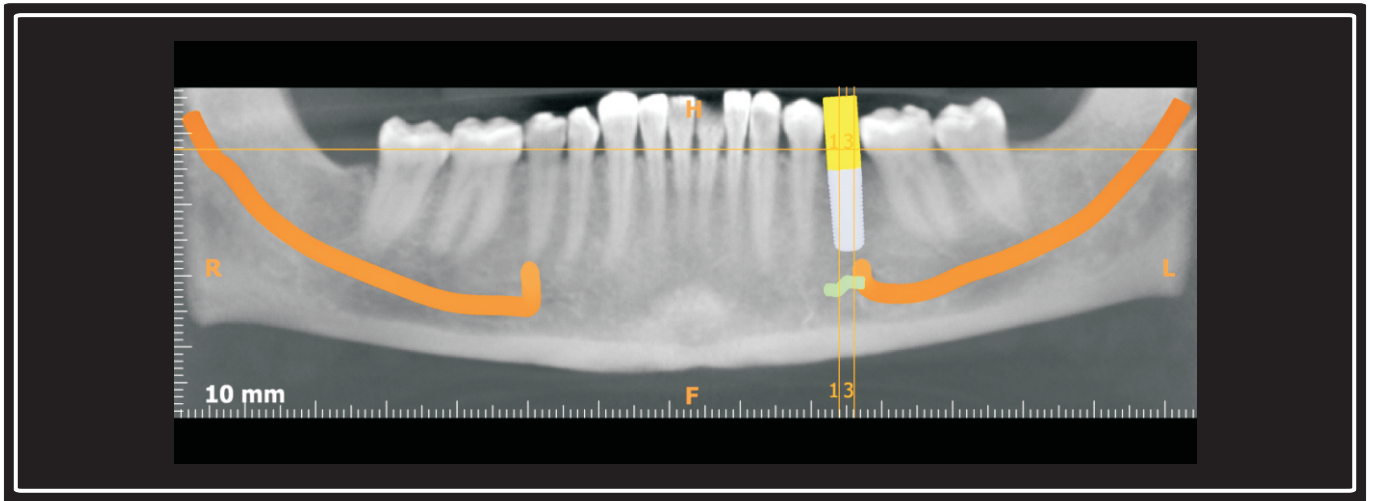
Axial image

Reconstructed panoramic image

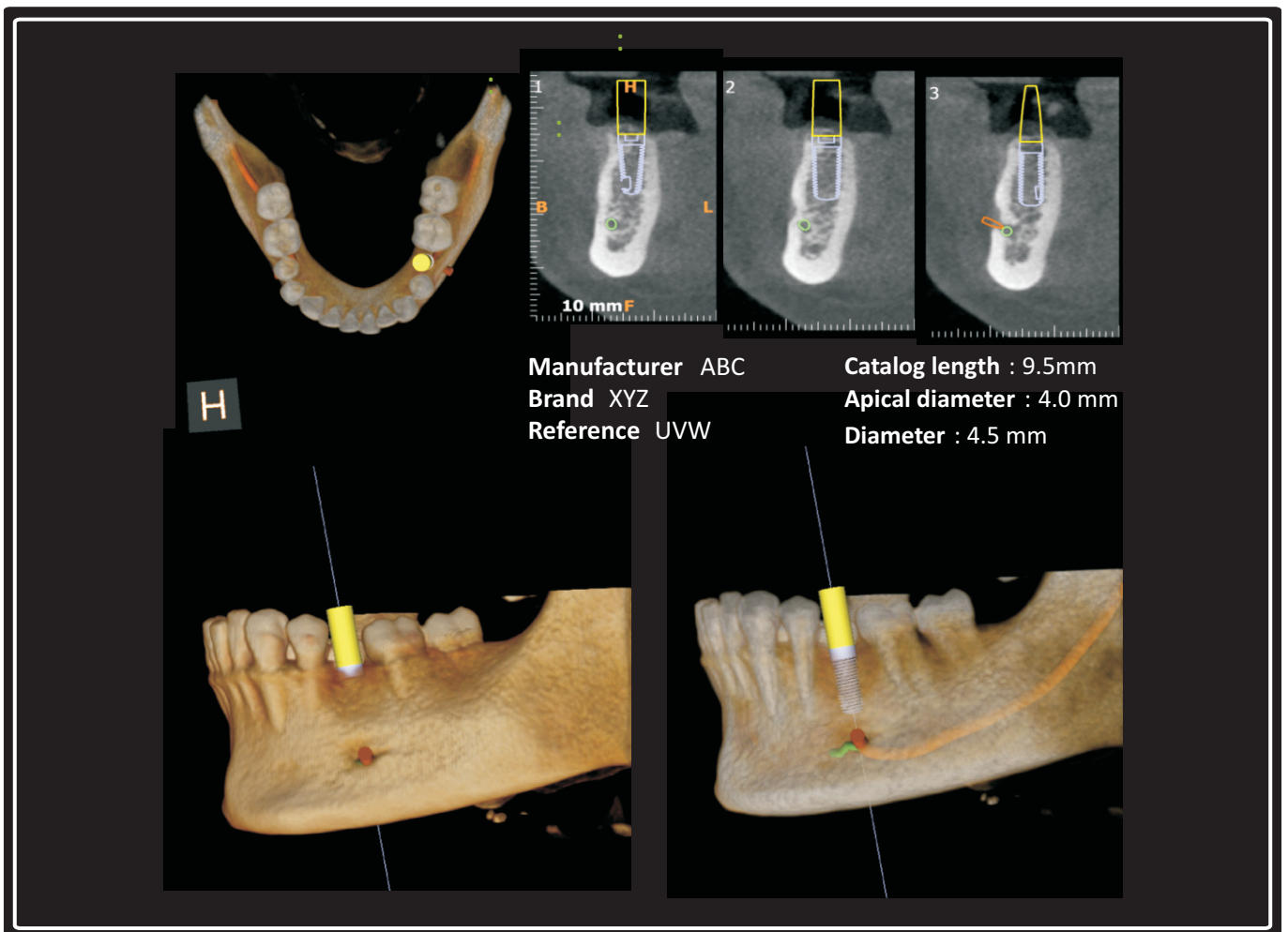


Crosssection Images - Slice thickness 0.18 mm, Slice spacing 1mm

## Virtual Implant



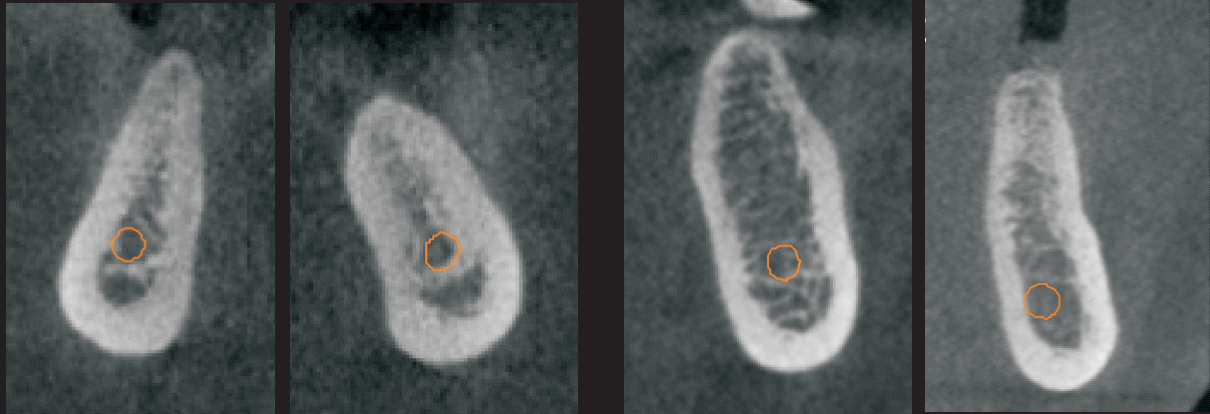
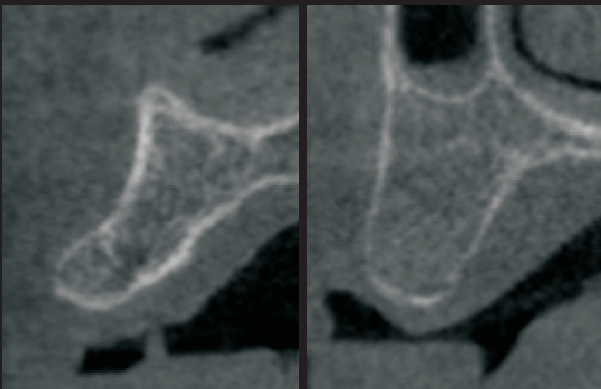
Reconstructed panoramic image



3 D View

Transparent 3 D View

## Misch Bone Density Classification

**D1****D2****D3****D4**

### Misch bone density classification

**D1** is primarily dense cortical bone.

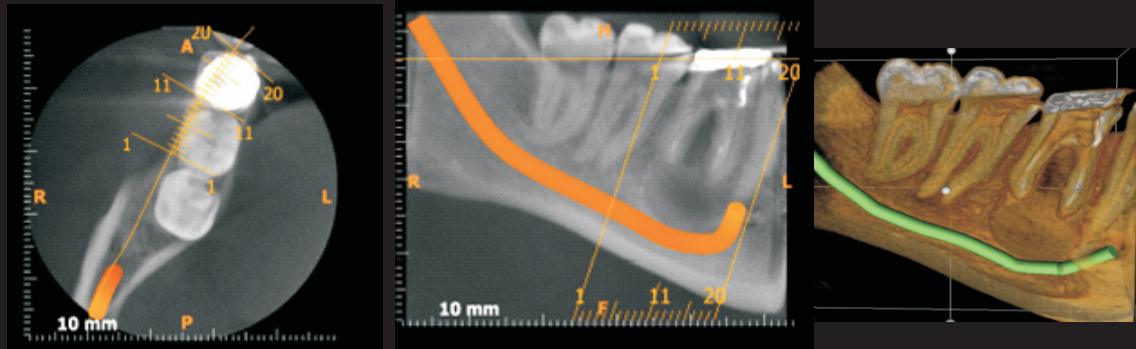
**D2** bone has dense to thick porous cortical bone on the crest and within coarse trabecular bone.

**D3** has thinner porous cortical crest and fine trabecular bone.

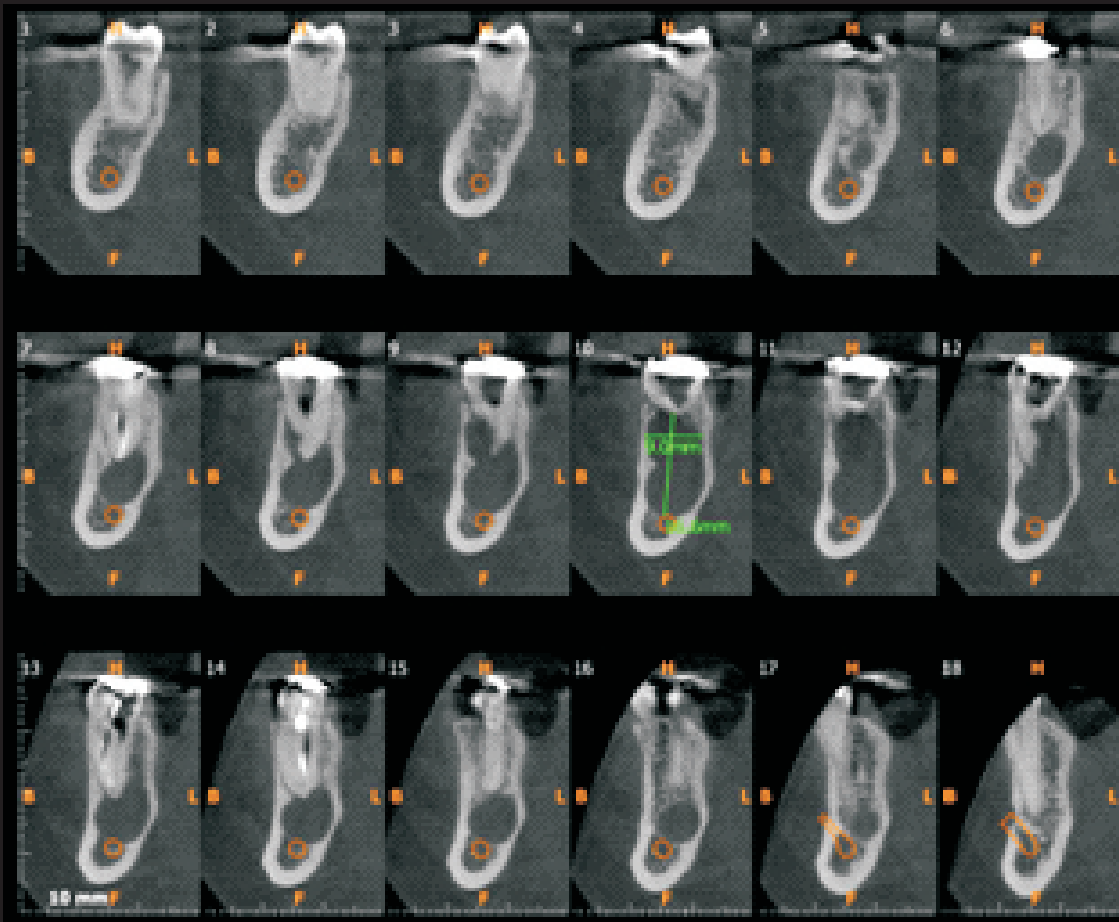
**D4** has no crestal cortical bone.



## Radicular Cyst

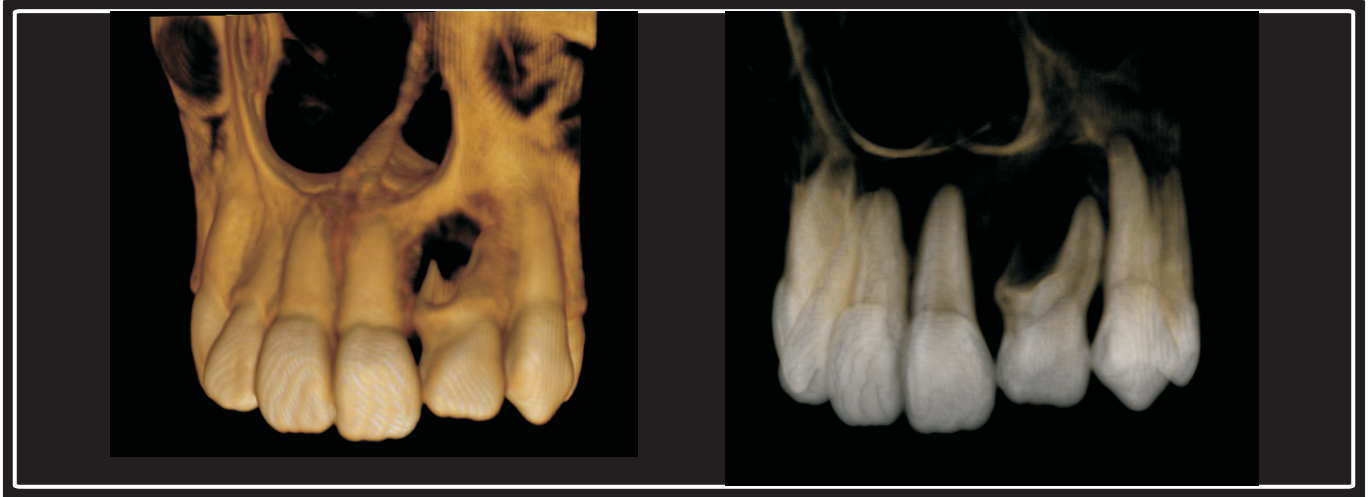

3D view



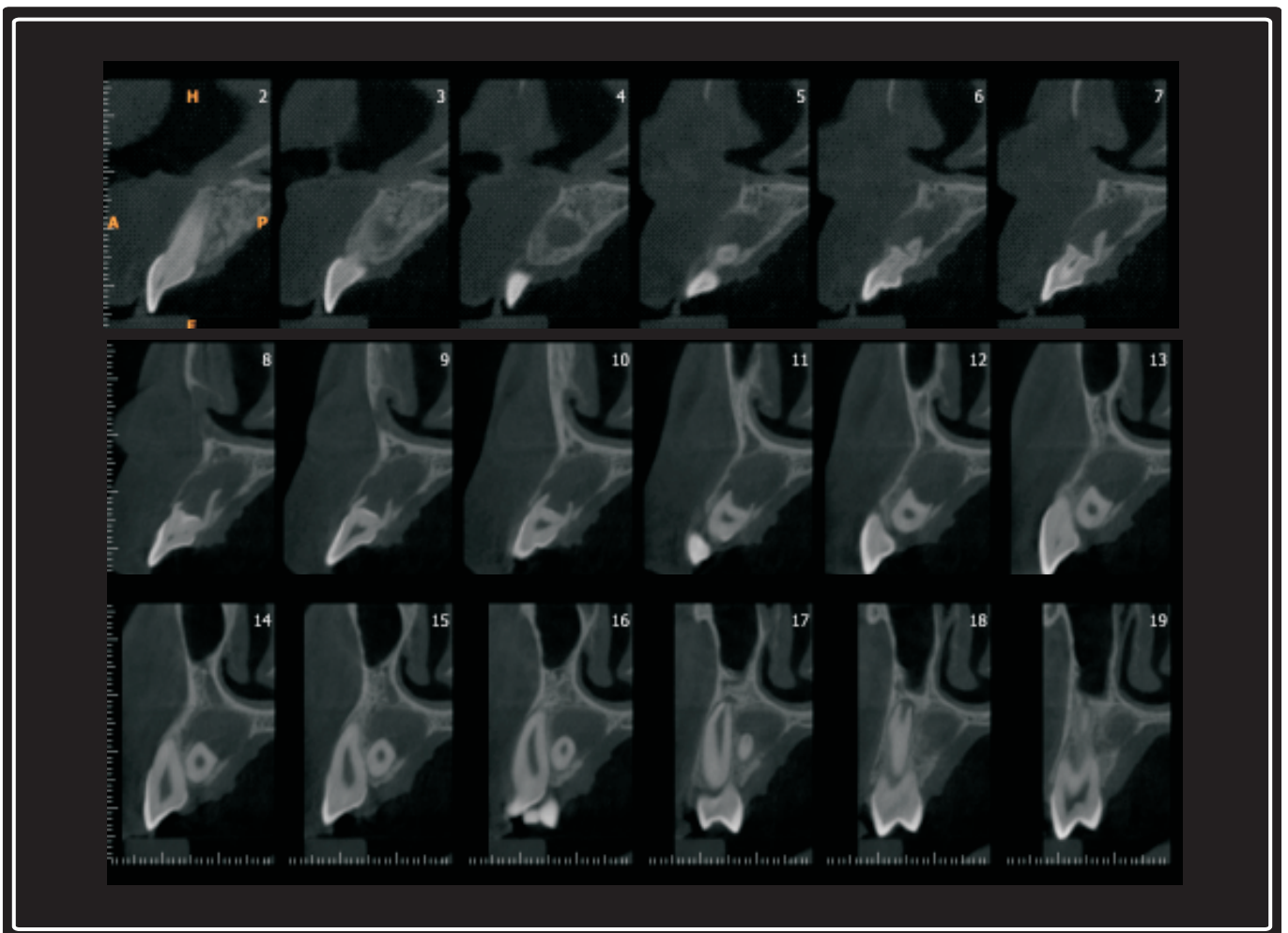
Crosssection Images - Slice thickness 0.18 mm, Slice spacing 1mm

## Dens Invaginatus with Periapical Cyst



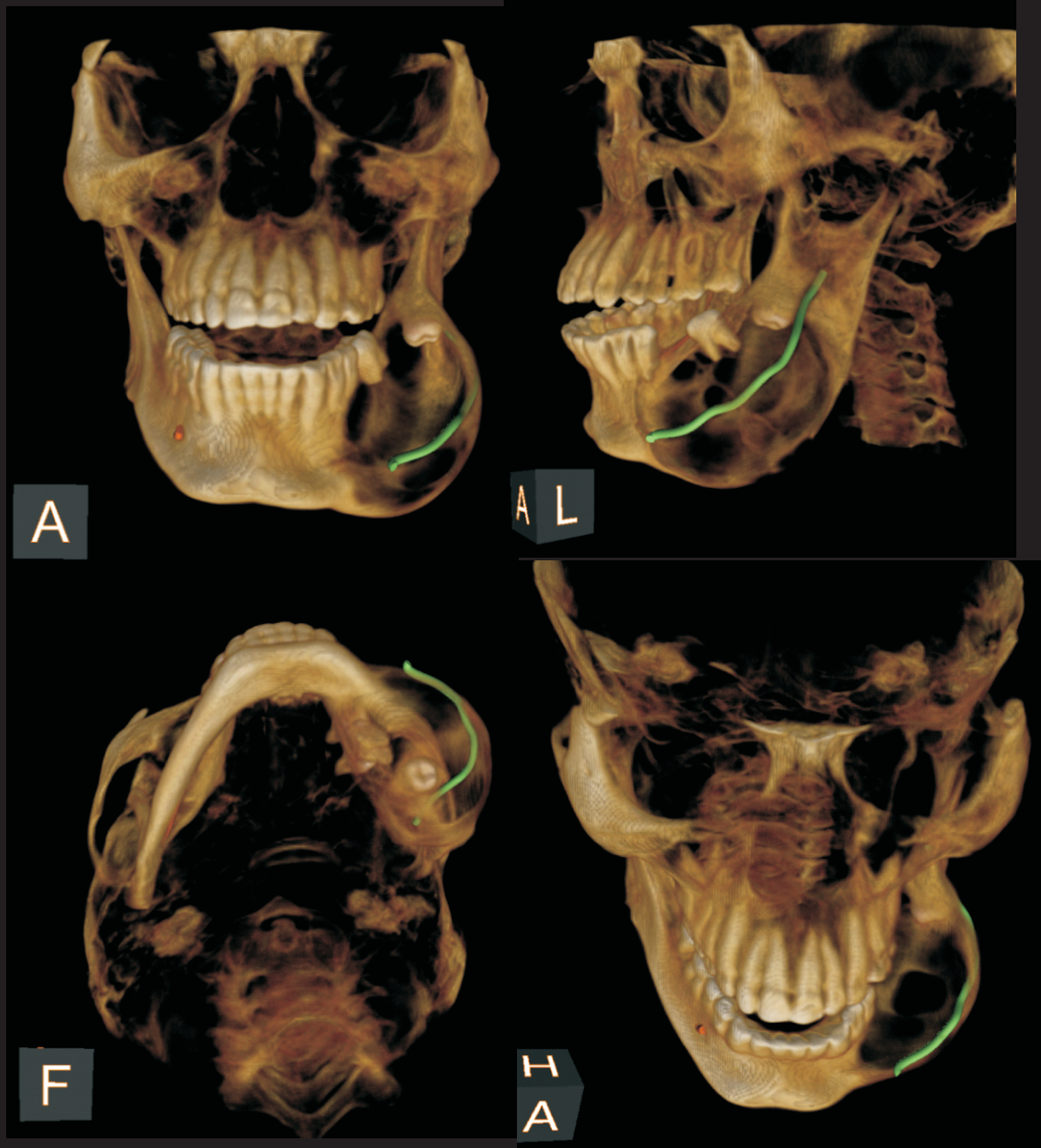
3D View

Transparent 3D View



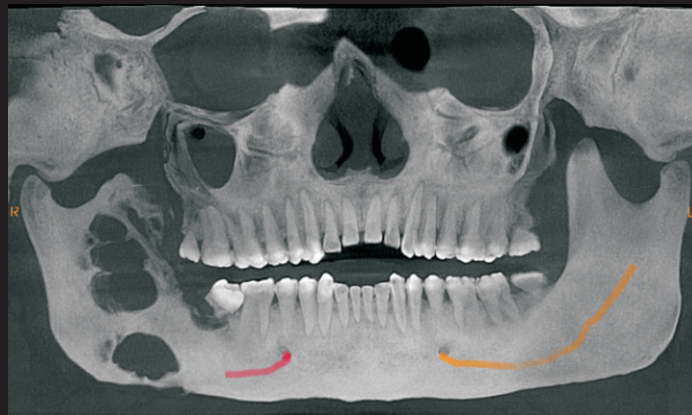
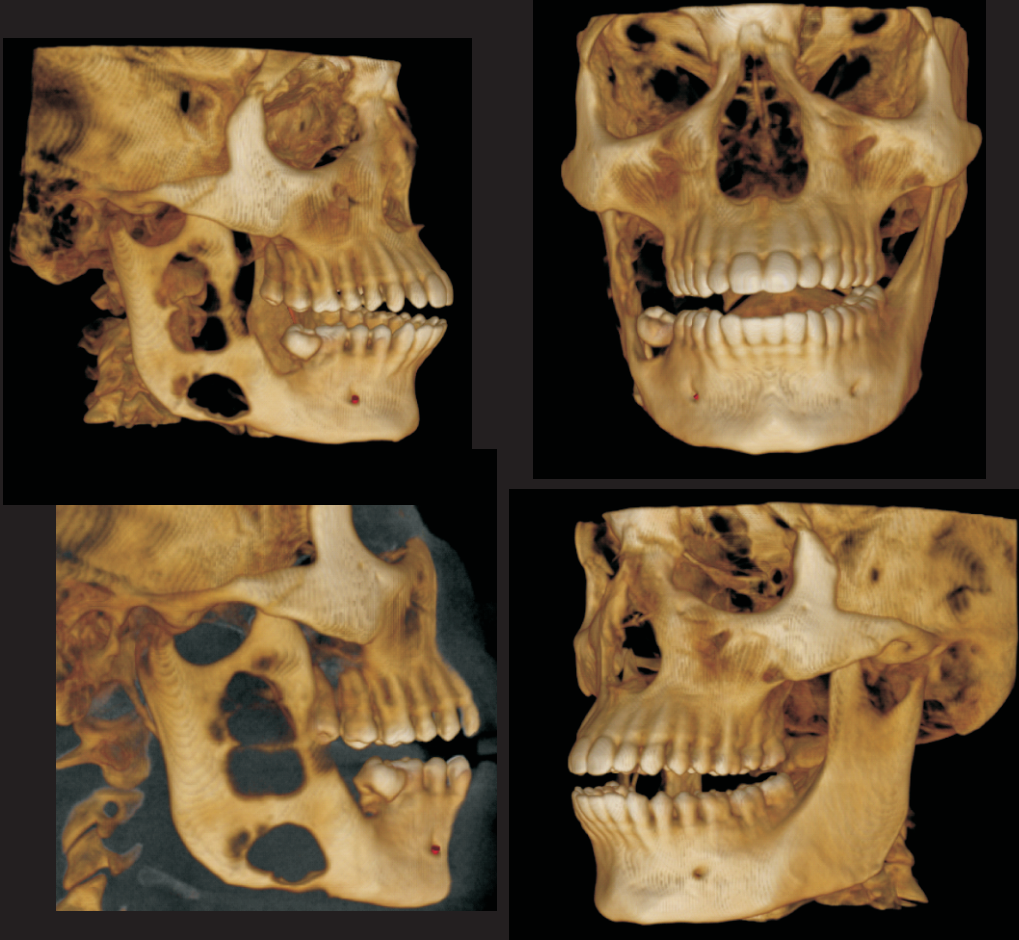
Crosssection View - Slice thickness 0.18 mm, Slice spacing 1mm

## Ameloblastoma



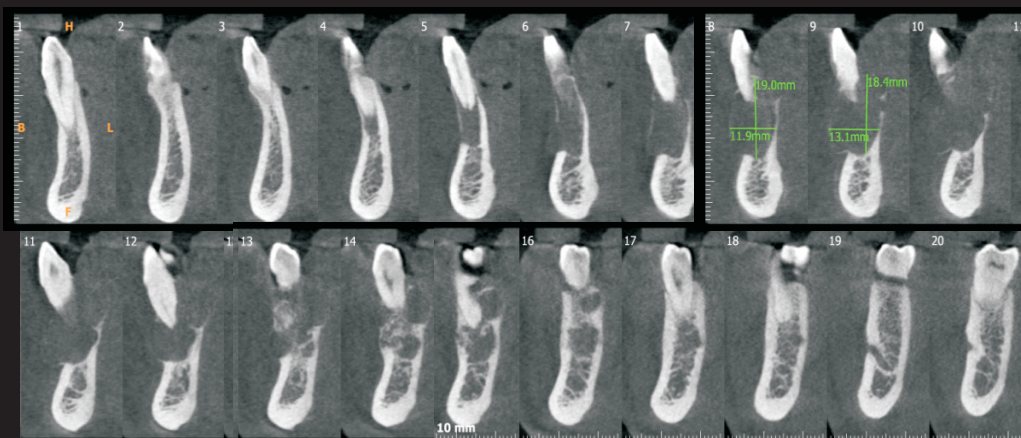
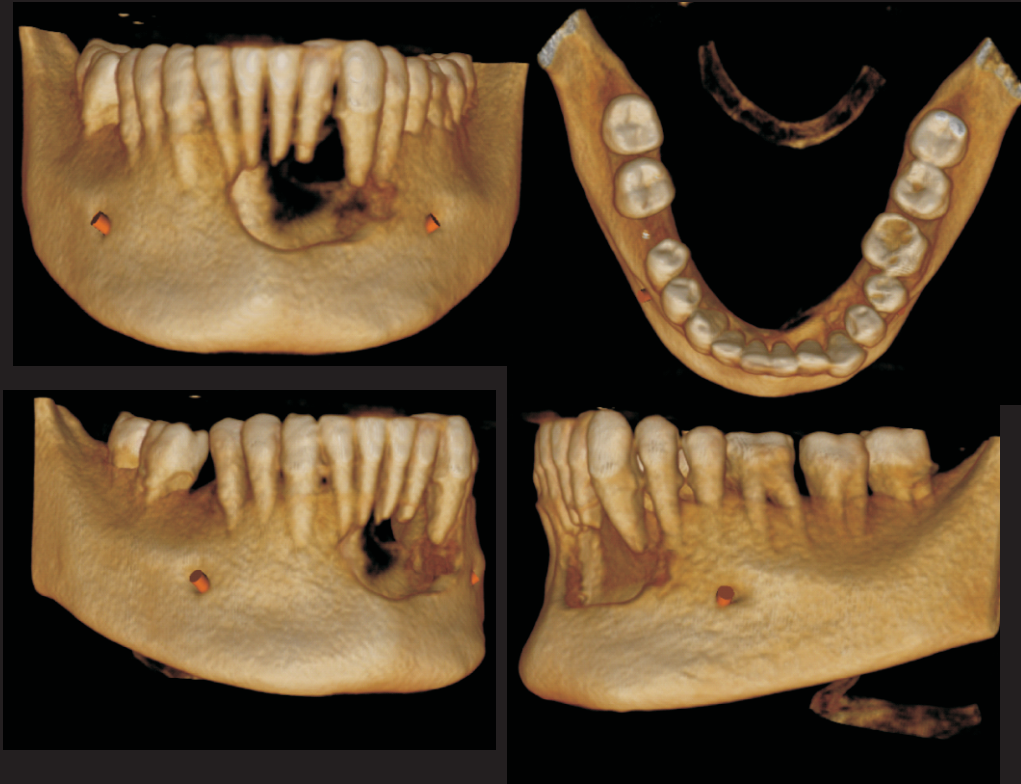

## Odontogenic kerato cyst



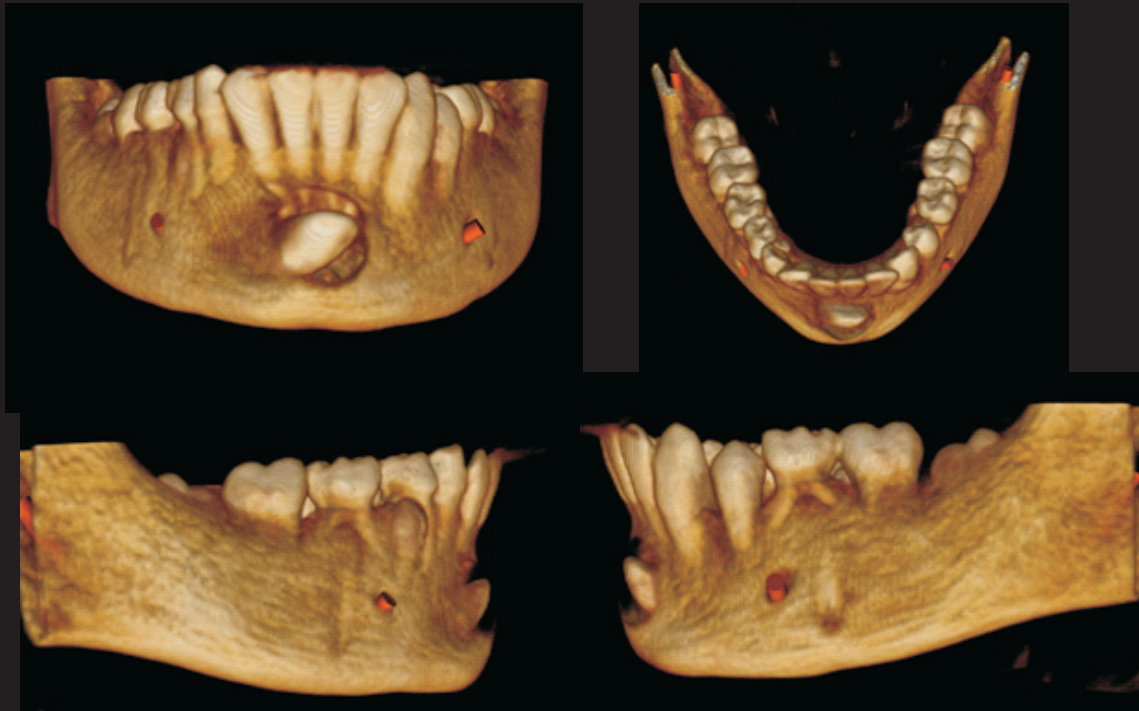
MIP Image Reconstructed Panoramic Image

## Central Giant Cell Granuloma

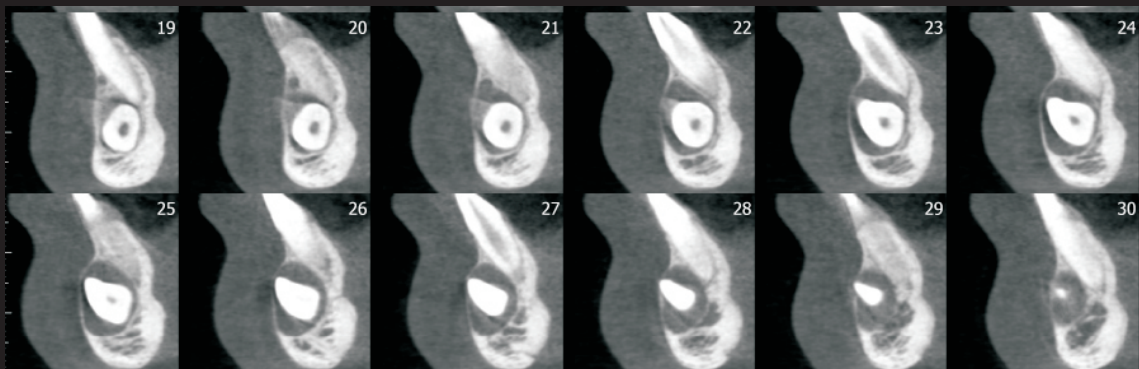


Cross-section

## Dentigerous Cyst



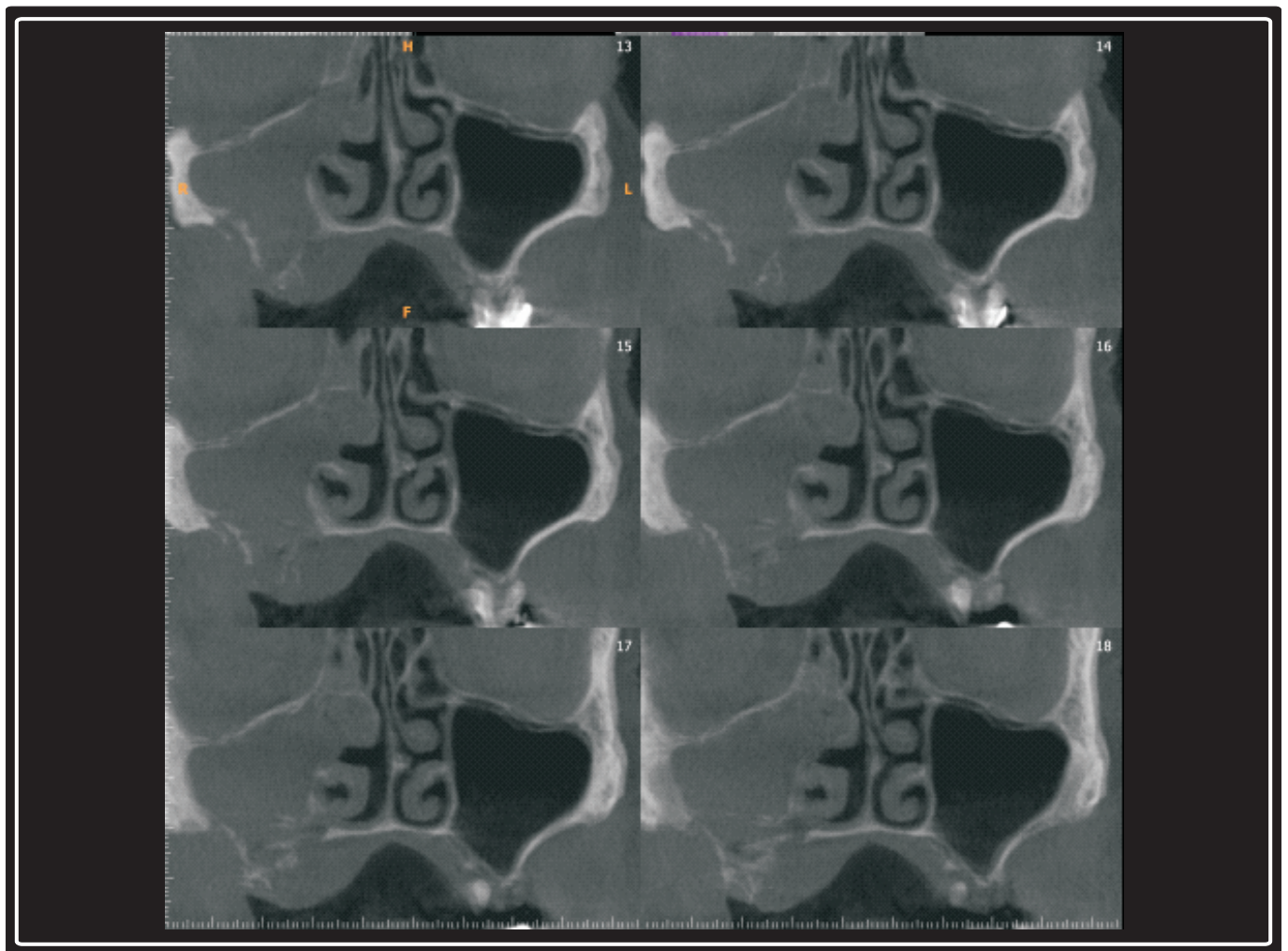
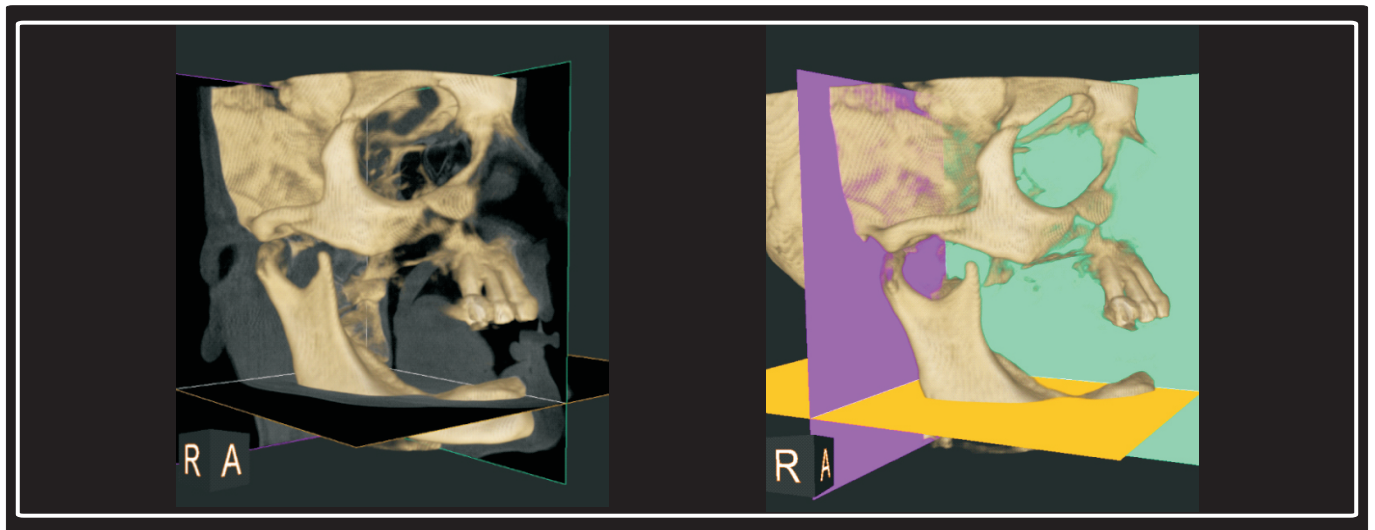
3D View Mandible



Cross-section

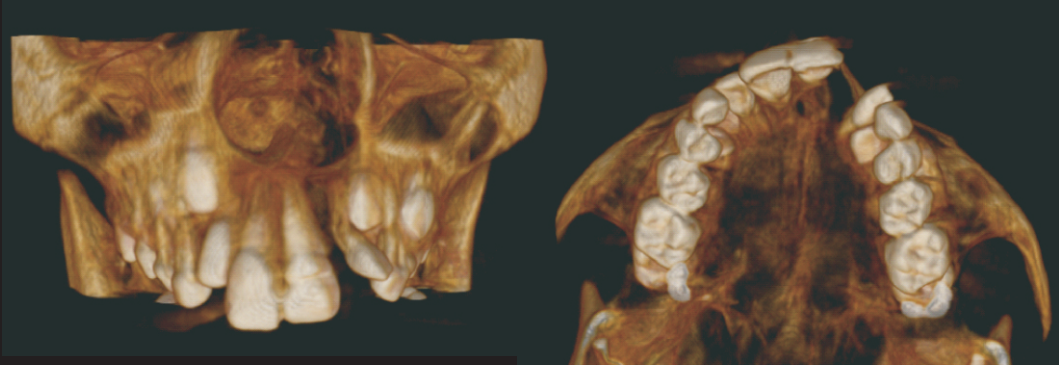


## Mucormycosis of Maxilla

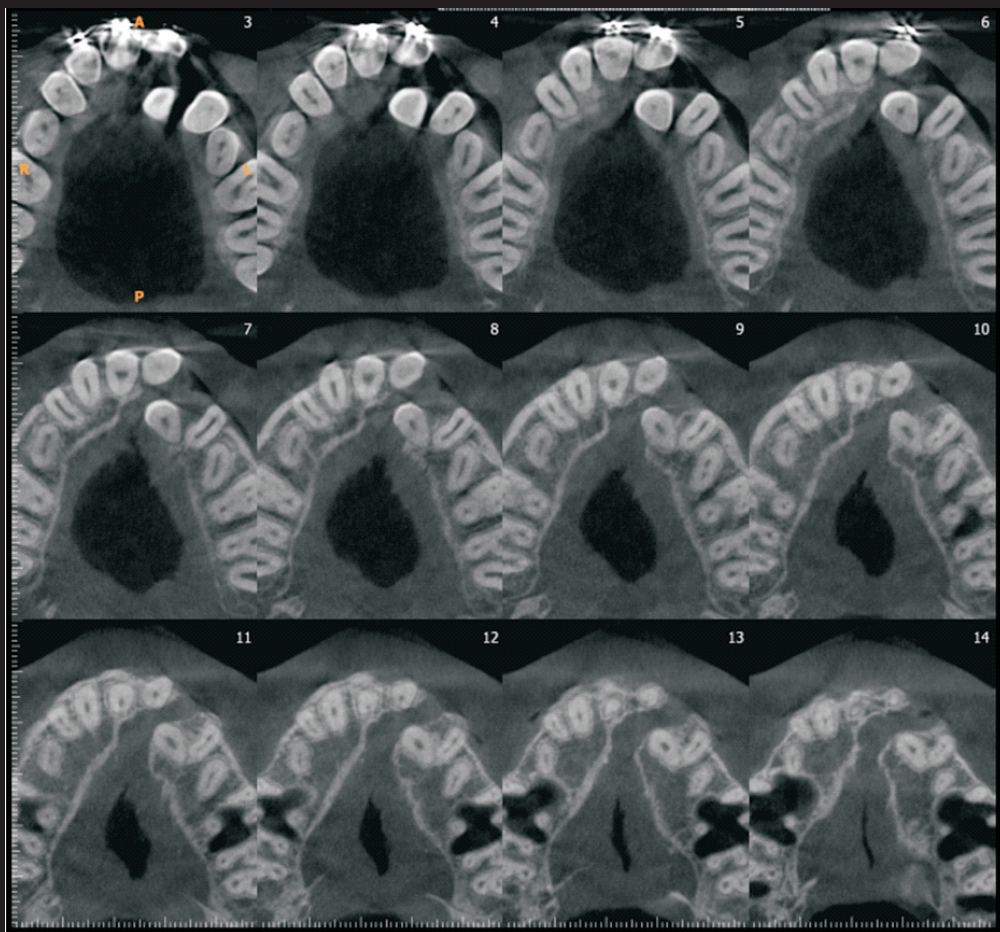


Coronal Section

## Cleft Palate



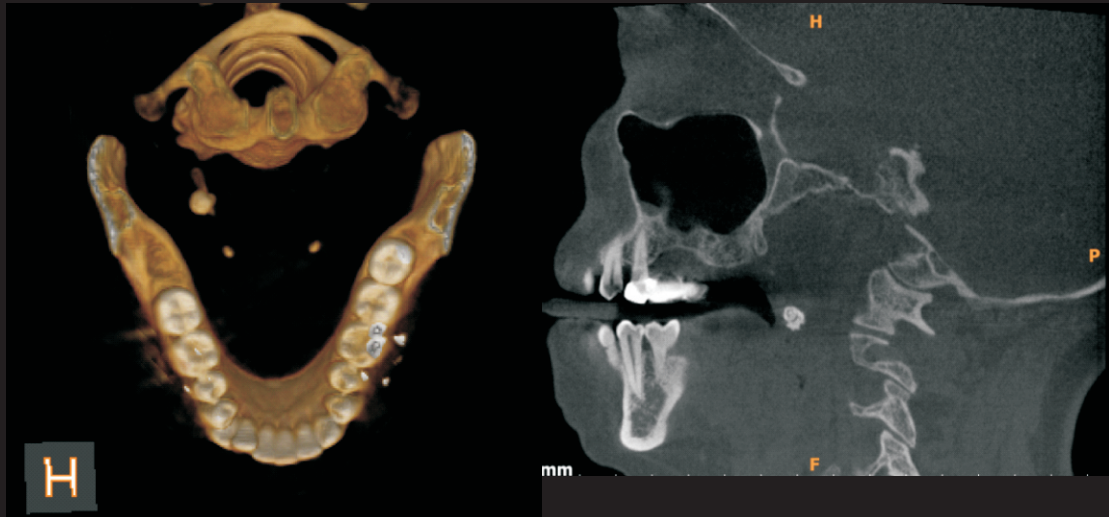3D View Maxilla



Axial Section

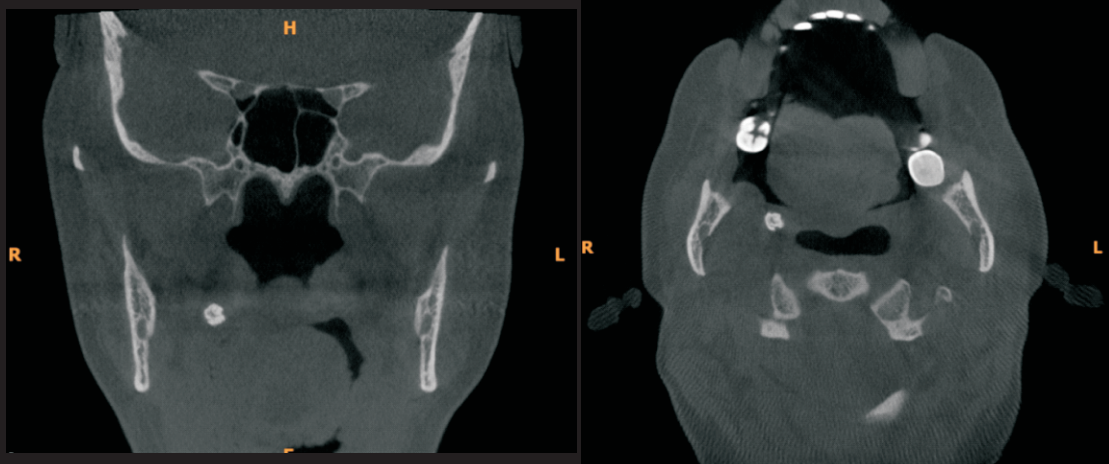

## Soft Tissue Calcification (Tonsilolith)



3D View

Sagittal Section

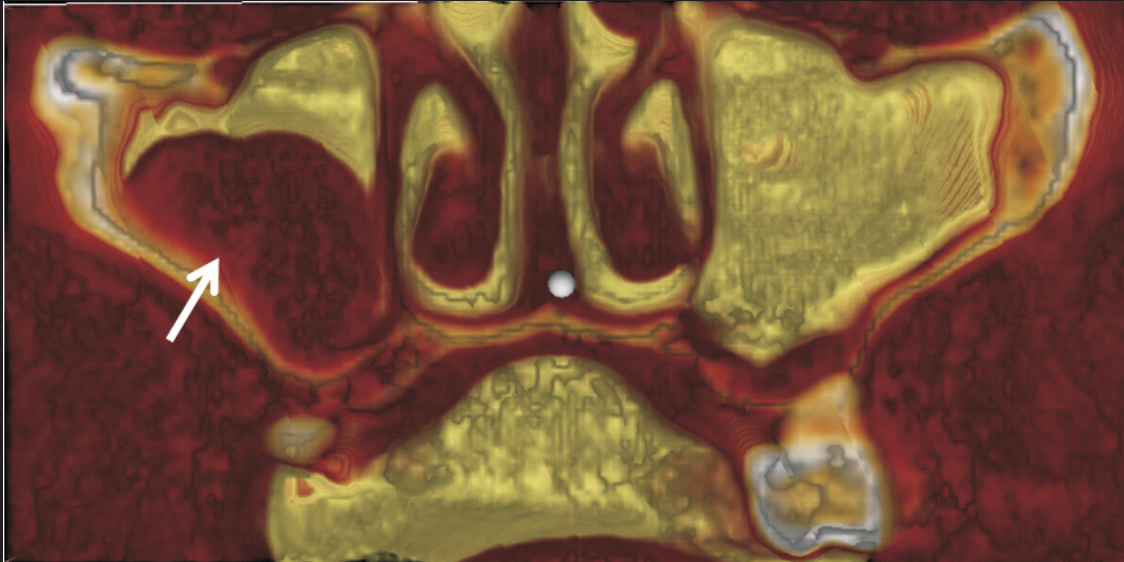


Coronal Section

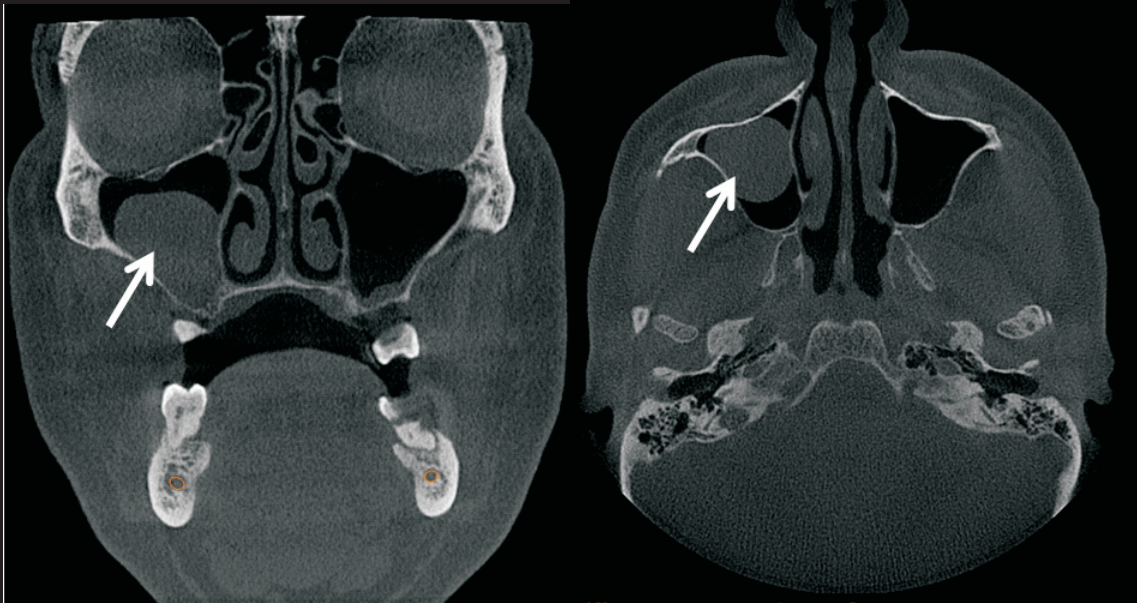
Axial Section



## Antral Polyp



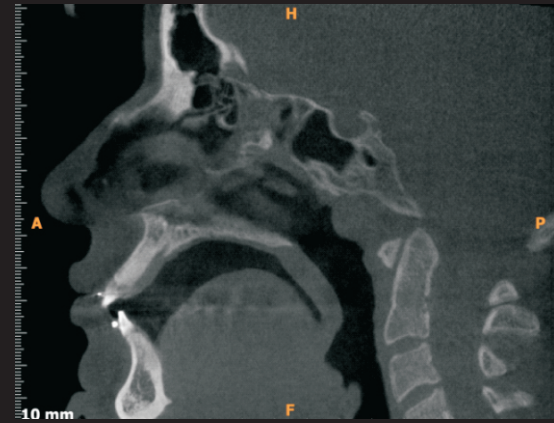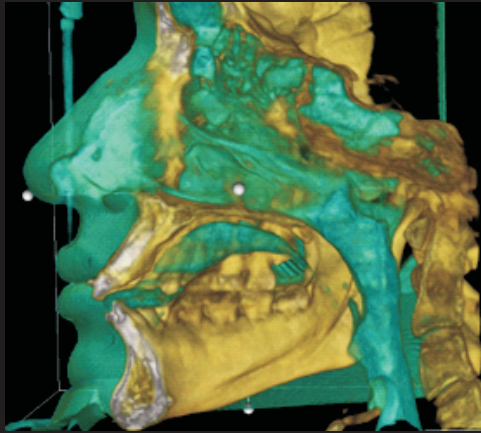
Cropped Reconstructed 3D view



Coronal Section

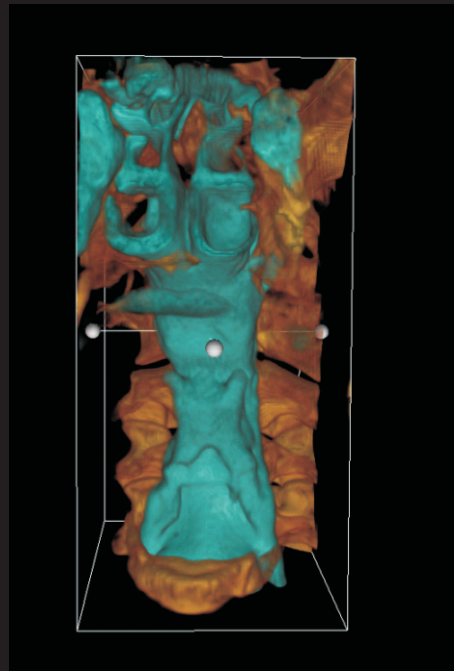
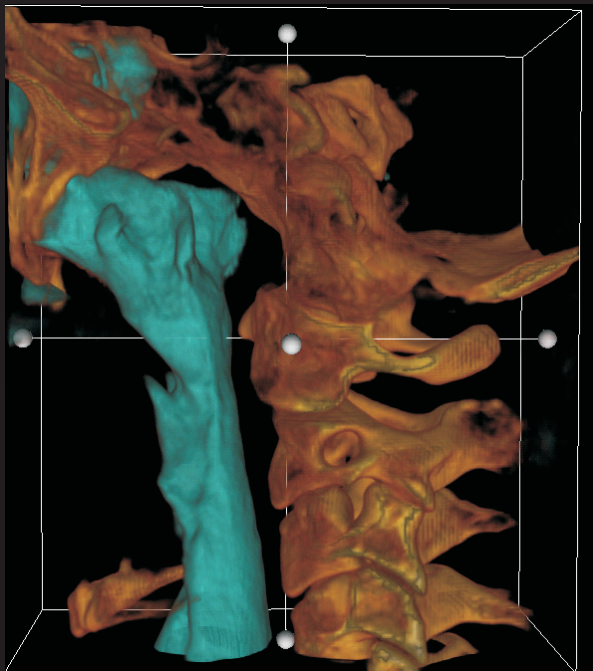
Axial Section

## Airway Study



Cropped Reconstructed 3D view

Sagittal Section



Cropped - Reconstructed 3D View